Skallebasiskirurgi

Sinan Dheyauldeen

Overlege ØNH-Rikshospitalet

Førsteamanuensis-UiO

Oslo universitetssykehus

Disposisjon

- Anatomi
- Krav
- Mål
- Eksempler

Anatomi

Anatomi

- **<u>Skallebasis:</u>** gulvet til kranialhulen som skiller hjernen fra andre ansiktsstrukturer.

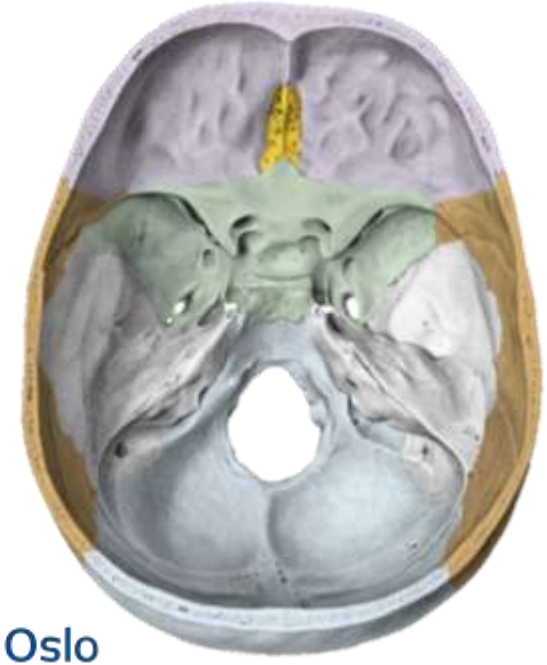

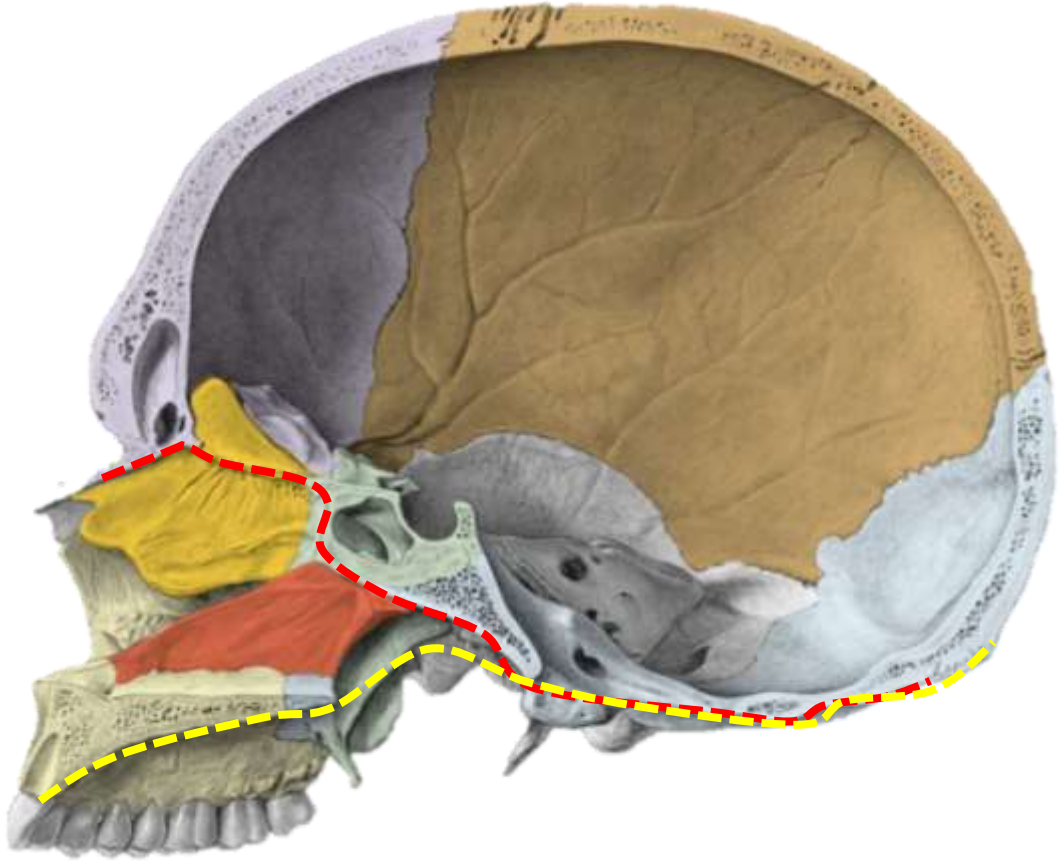

Oslo universitetssykehus

Anatomi

- 3 Region
  1. Anteriort
  2. Lateralt (Midtre)
  3. Posteriort

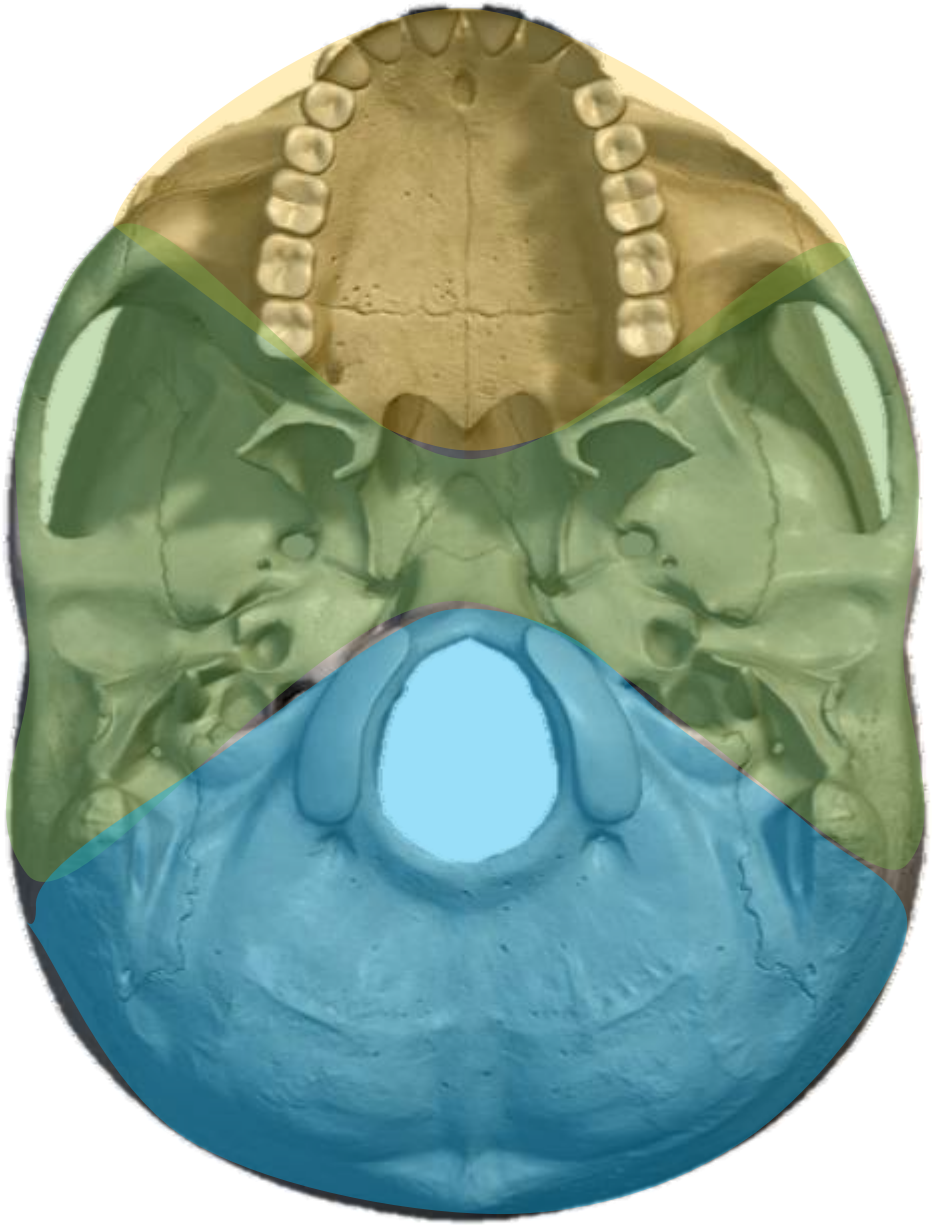

Oslo universitetssykehus

Anatomi

Foramen

Foramen cecum

Optisk foramen (Canal)

Foramen lacerum

Foramen rotundum

Foramen magnum

Foramen ovale

Jugular foramen

Intern auditiv meatus

Mastoid foramen

Foramen spinosum

Hypoglossal canal

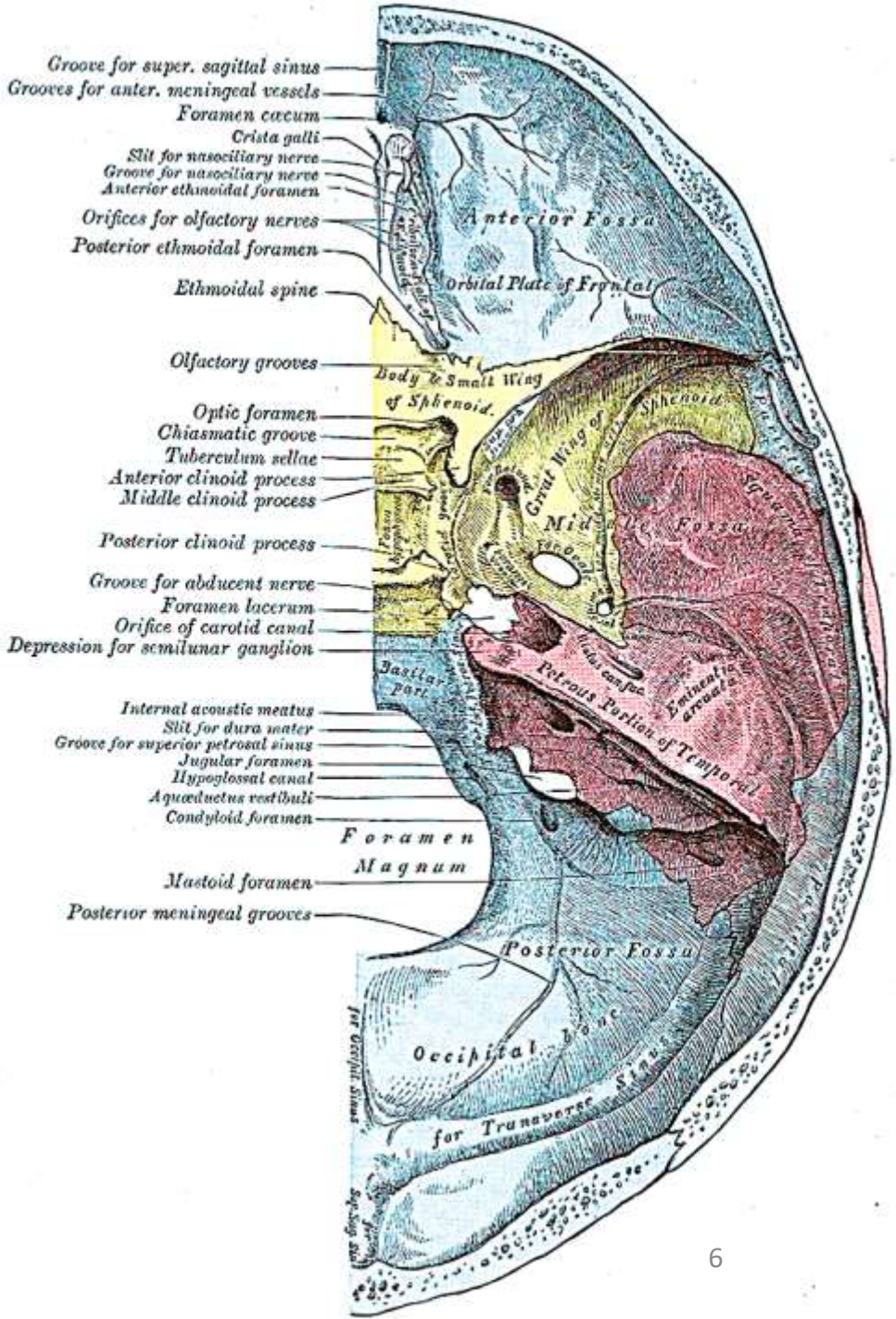

Anatomi

Foramen	Content
Foramen cecum	Emissary vein
Optisk foramen (Canal)	Optic n., ophthalmic a.,& sympathetic fibres
Foramen lacerum	Vidian n., v. & a.
Foramen rotundum	V2
Foramen magnum	Spinal cord
Foramen ovale	V3
Jugular foramen	Jugular v., IX, X, & XI
Intern auditiv meatus	VII, VIII
Mastoid foramen	VII
Foramen spinosum	Middle meningeal a.
Hypoglossal canal	XII

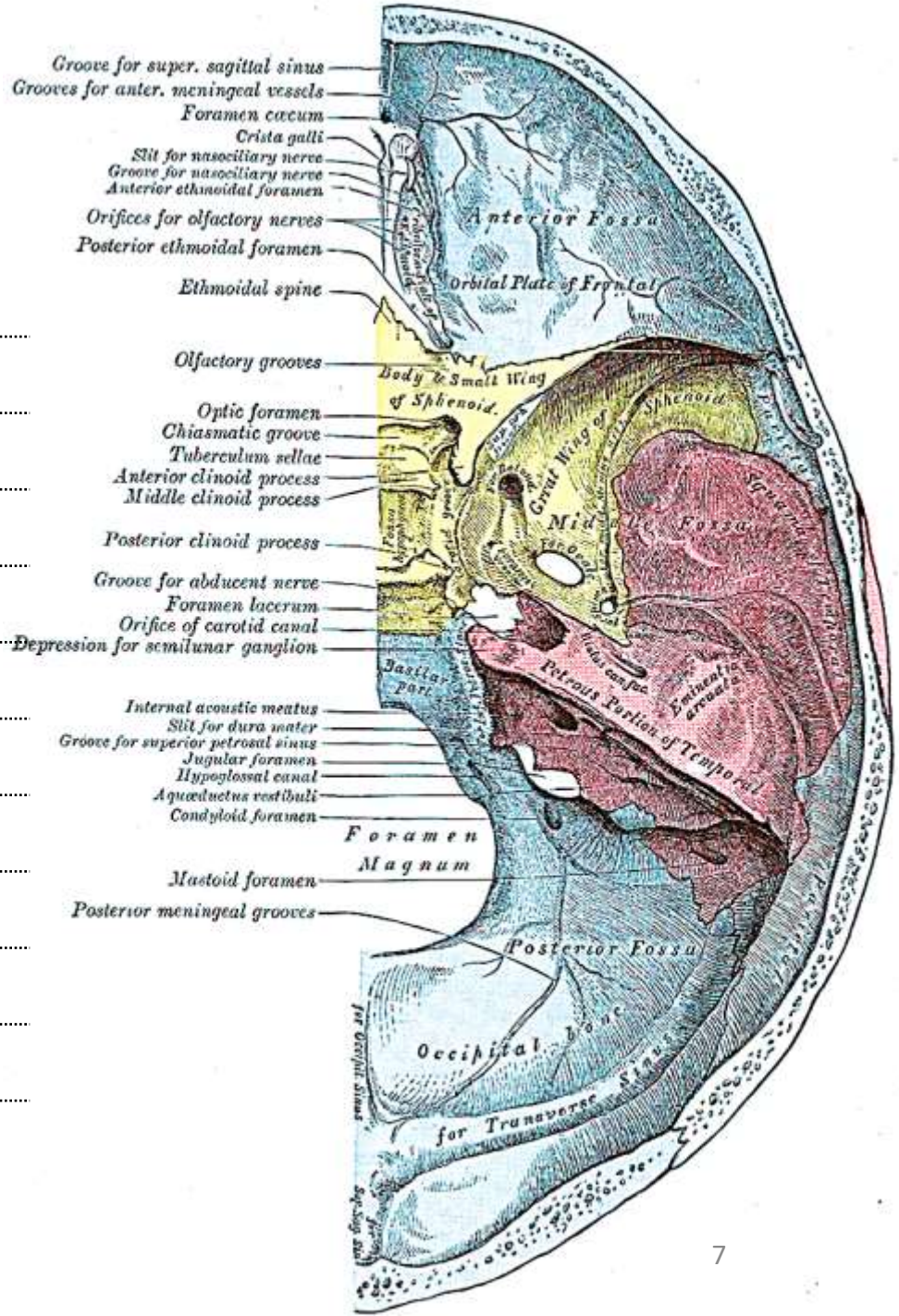

Krav for skallebasis kirurgi

- Kunnskap
- Utstyr
- Samarbeid

Krav for skallebasis kirurgi

- Kunnskap
- Utstyr
- Samarbeid

Kunnskap

- Bøker
- Kongress
- Kurs
- Hospitering

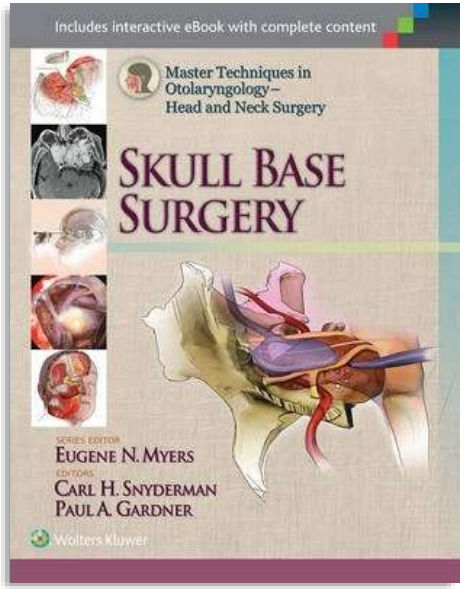

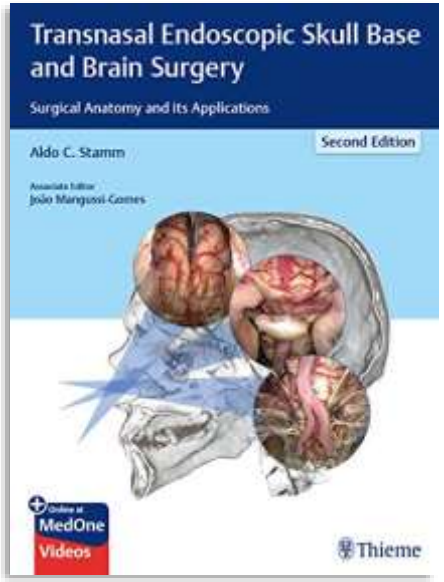

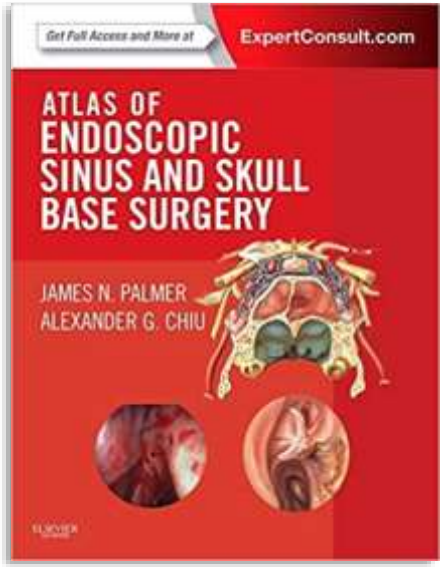

Oslo universitetssykehus

Krav for skallebasis kirurgi

- Kunnskap
- Utstyr
- Samarbeid

Utstyr

- Visualisering
- Lokalisering
- Disseksjon
- Hemostase

Utstyr

- Visualisering *(see more> do more)*
    - Endoskop

Utstyr

- Visualisering *(see more> do more)*
    - Endoskop
        - Rack (Skjerm)

Utstyr

- Visualisering *(see more> do more)*
    - Endoskop
        - Rack (Skjerm)
    - Lupebriller
    - Mikroskop

Utstyr

- Visualisering *(see more> do more)*
    - Endoskop
        - Rack (Skjerm)
    - Lupebriller
    - Mikroskop

Plassering av instrumentene

1 Kirurg (ØNH)

2 Kirurg (ØNH + Nevrokirurg)

Ofte 0 grader optikk kl 12 i hø nesebor

Plassering (Endoskopisk 4 hånd)

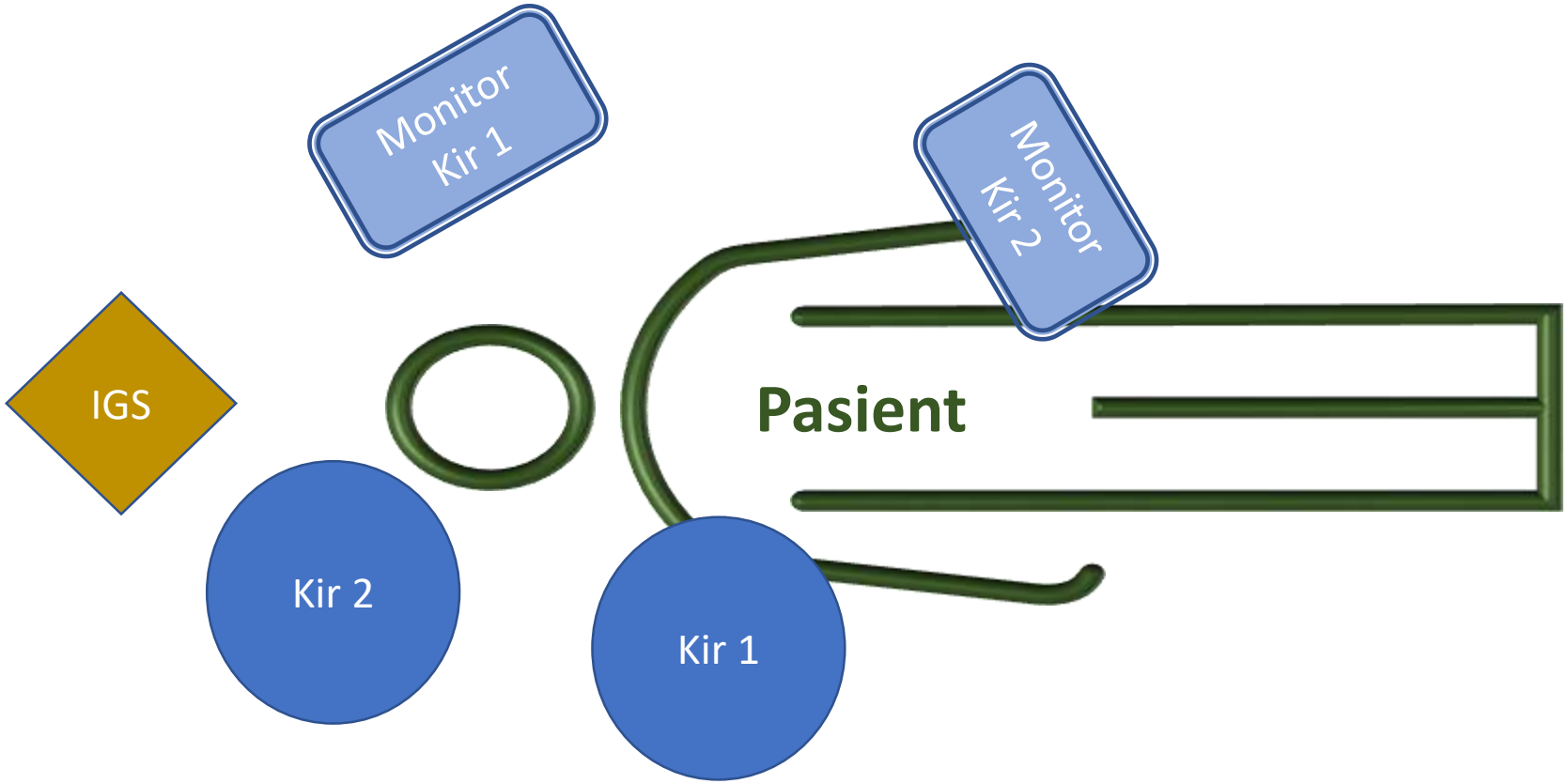

Plassering

Oslo universitetssykehus

Plassering (Endoskopisk 2 hånd)

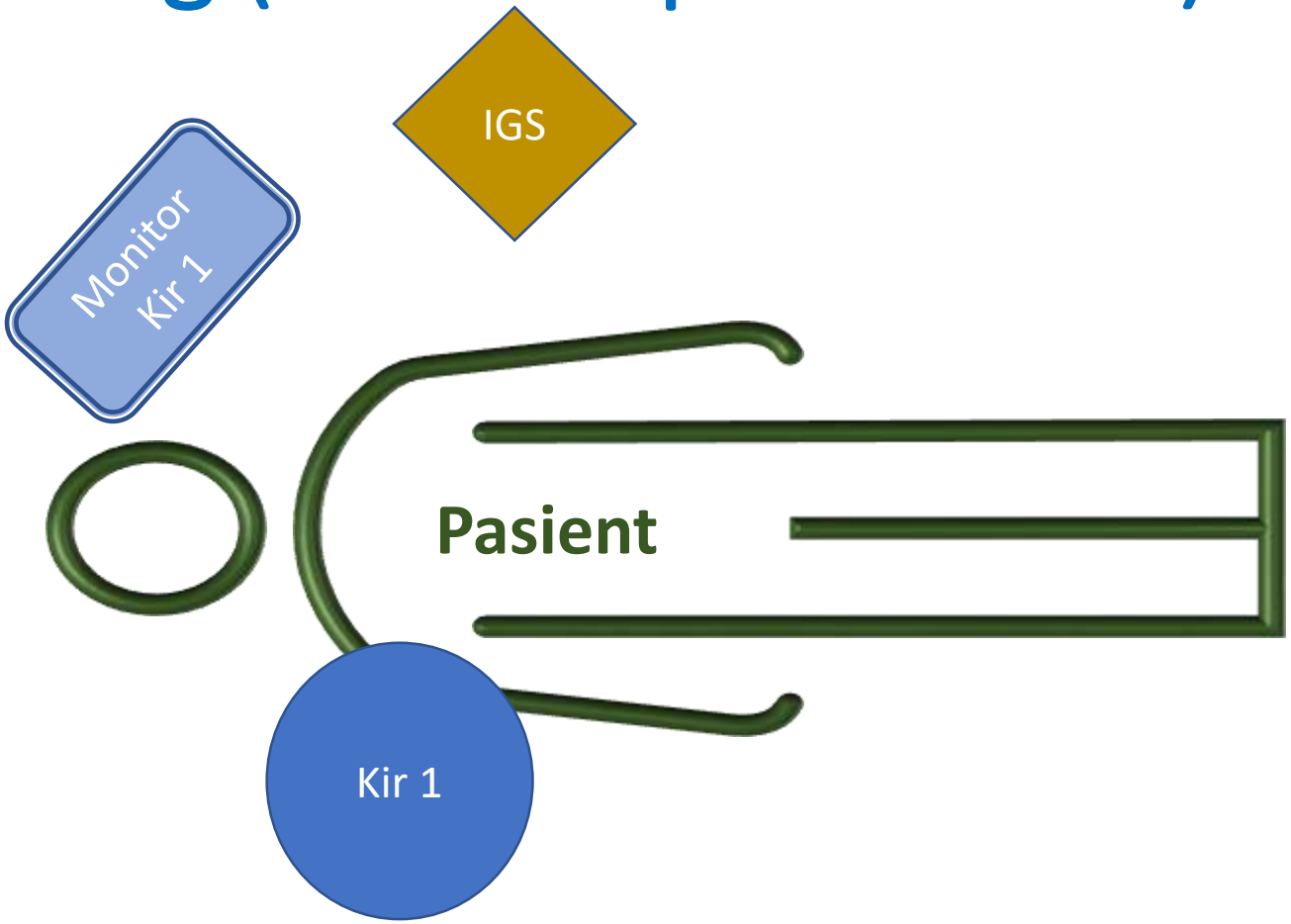

Plassering (Åpen tilgang)

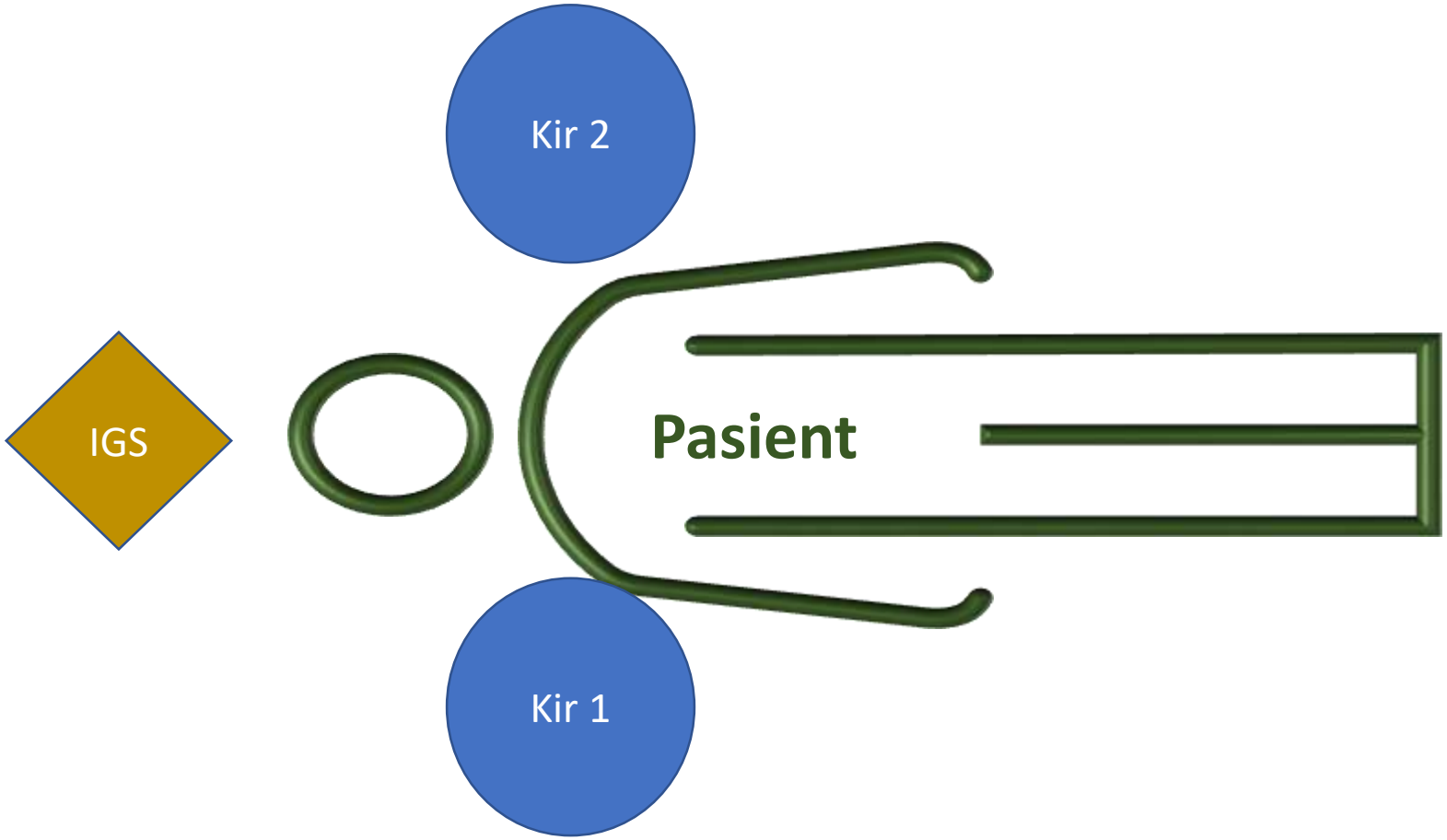

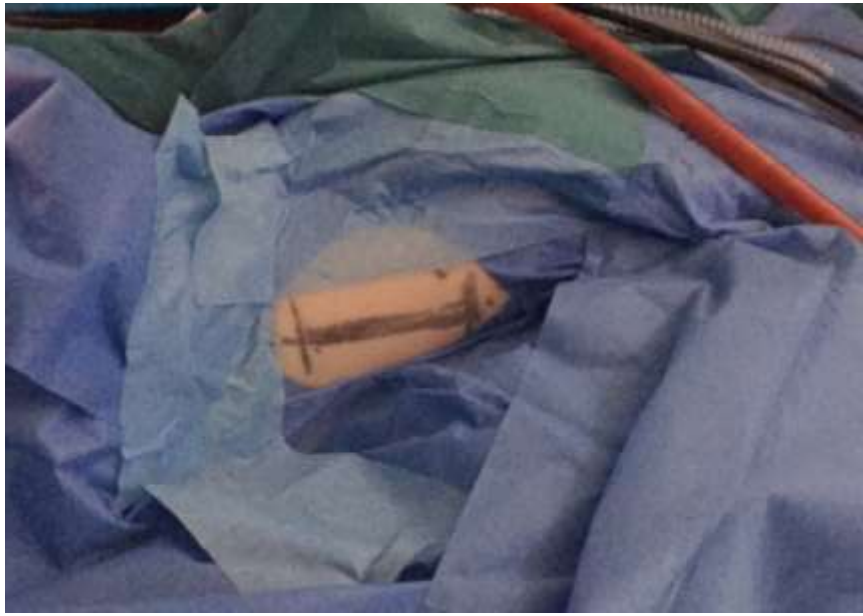

TRANSPHENOIDAL ENDOSKOPISK HYPOFYSEOPERASJON

Brainlab og stor skjerm.

Endoskopirack, diatermirack og Midas Rex til Shaver.

Rekkefølge på pedaler.

Høyre arm fiksert i stikklaken polstret med liten gelematter. Felt til høsting av fett fra mage. Desinfeseres og dekkes fra start.

Merking av sug ved bruk av Shaver. Sug med kulesug og Shaver settes på samme sugeapparat. Sug med nr 12 sug settes på det andre sugeapparatet. Når Shaver brukes settes suget opp på 10

Møblering av opr.stua ved opr med både Transpheniodal og Craniotomi tilgang:

FØR OPERASJON:

Craniotomi til **venstre**

- Innerst hø side:

  Mikroskop-Brainlab skjerm

  Brainlab øyne-Storskjerm

- Transphenoidal til **høyre**

UNDER OPERASJON:

- Mikroskop står midt på vindu
- Storskjerm trekkes mot vindu

- Endoskopirack inntil opr bord. (der står evt Midas Rex til shaver)
- Ø-hjelpsrack ved siden av, brukes til **Transphenoidal utstyr**
- Ekstra trillesug til evt shaver.
- Diatermirack i fotende, brukes til **Craniotomi utstyr**

Utstyr

- Lokalisering
  - IGS (Navigasjon)

Utstyr

- Lokalisering
  - IGS (Navigasjon)
  - EMG (Hjernenerve overvåkning)

Utstyr

- Lokalisering
  - IGS (Navigasjon)
  - EMG (Hjernenerve overvåkning)
  - Endoskopisk Doppler

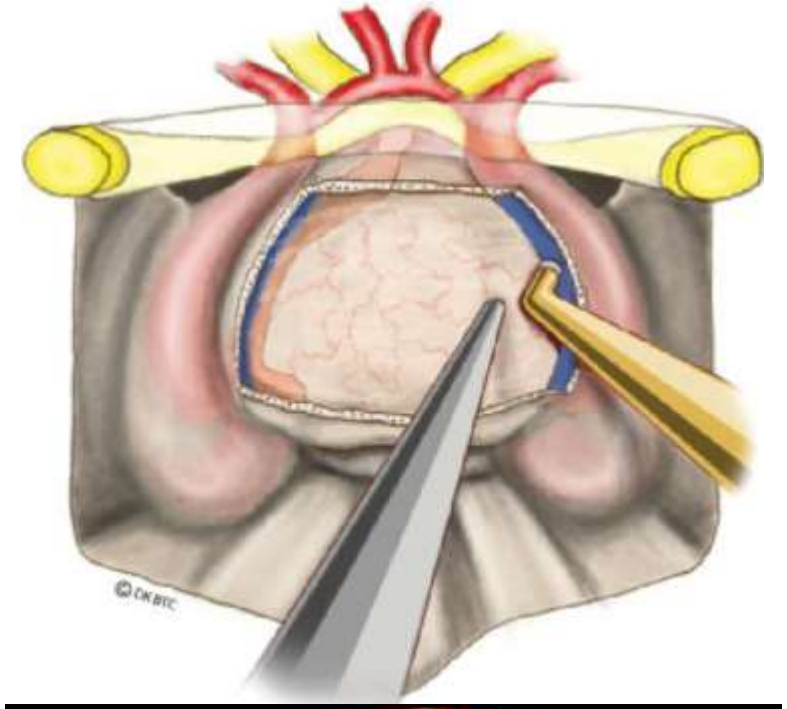

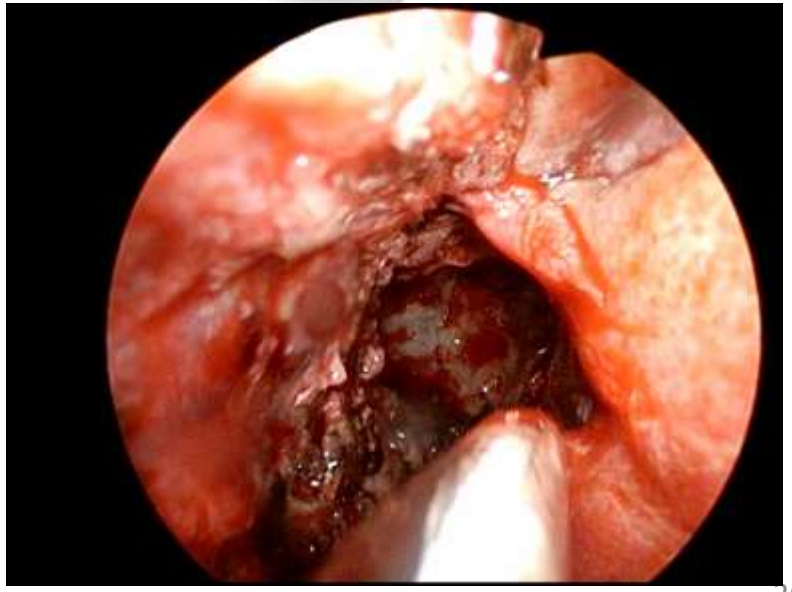

Oslo universitetssykehus

Utstyr

- Lokalisering
  - IGS (Navigasjon)
  - EMG (Hjernenerve overvåkning)
  - Endoskopisk Doppler
  - Intratekal flourescine

Intratekal Fluorescein

0,5 mg(av 100 mg / ml natrium floarescein) + 9 ml CSF

Oslo universitetssykehus

Utstyr

- Disseksjon utstyr
  - Borr
  - Microdissektor
  - Micro-tenger,-sax, -kniv…
  - Ultralydsdissektor
  - Coblasjon

Utstyr

- Hemostase teknikk
  - Diathermi
  - Klips
  - Varmtvann irrigering (40 grader)
  - Reverse Trendelenburg position
  - Homeostase faktorer (Surgiflo, Floseal, Sirraseal)

Oslo universitetssykehus

Hemostase

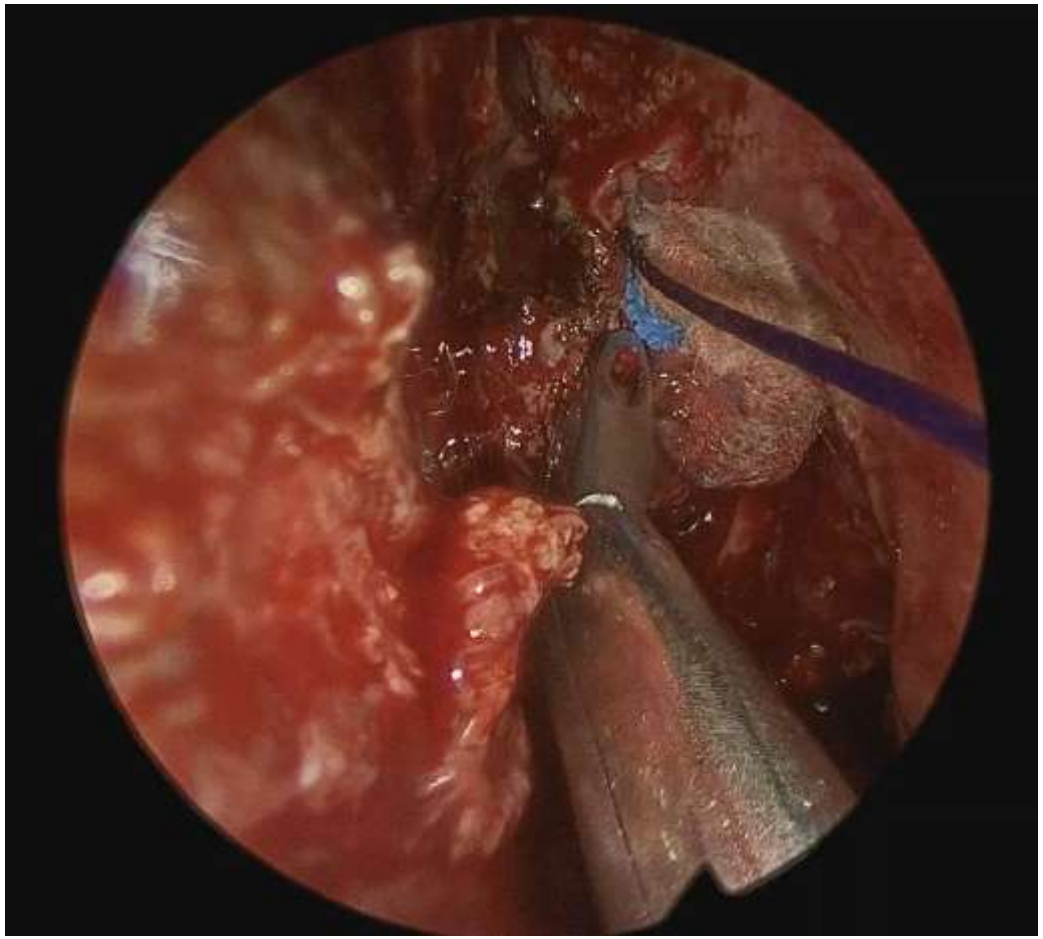

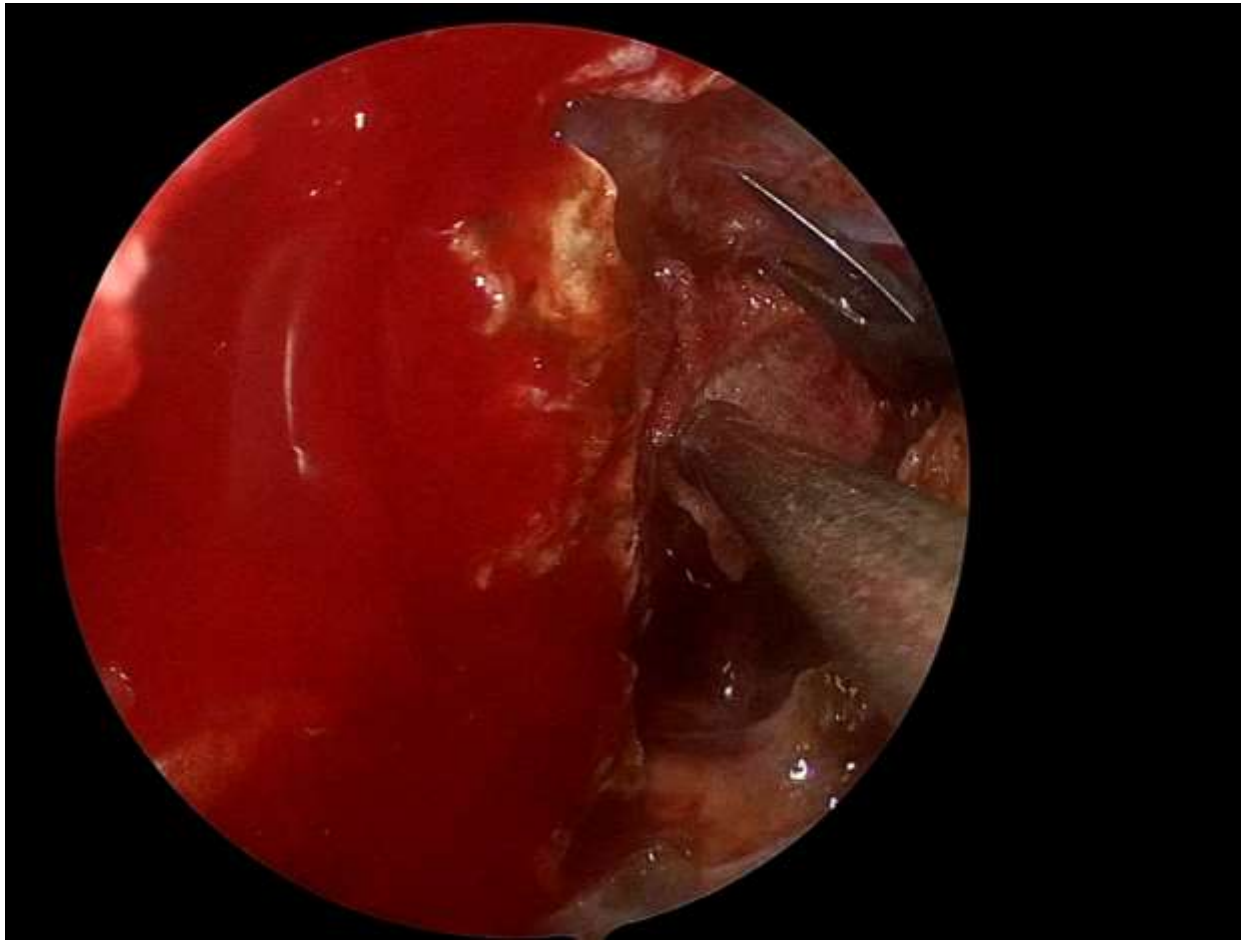

Ny teknologi ?

Krav for skallebasis kirurgi

- Kunnskap
- Utstyr
- Samarbeid

Samarbeid

- Hode og hals kirurg
- Nevrokirurgi
- Radiologi
  - Hode og hals radiolog
  - Nevroradiolog
  - Intervensjons radiolog
- Ophthalmologi
  - Okuloplast
- Onkolog
- Nevrolog
- Patolog
  - Nevropatolog
  - Hode og hals patolog

Forebredelse

- Pre-operativ angiografi / embolisering
- Ø.hjelp behandling for vaskulær skade
- Plan for lukking
- Per-operativ MR
- Blod
- Post-operativ intensiv

Oslo universitetssykehus

Mål av kirurgi

- Tetting av CSF lekkasje
- Komplisert CRS
- Tumor kirurgi

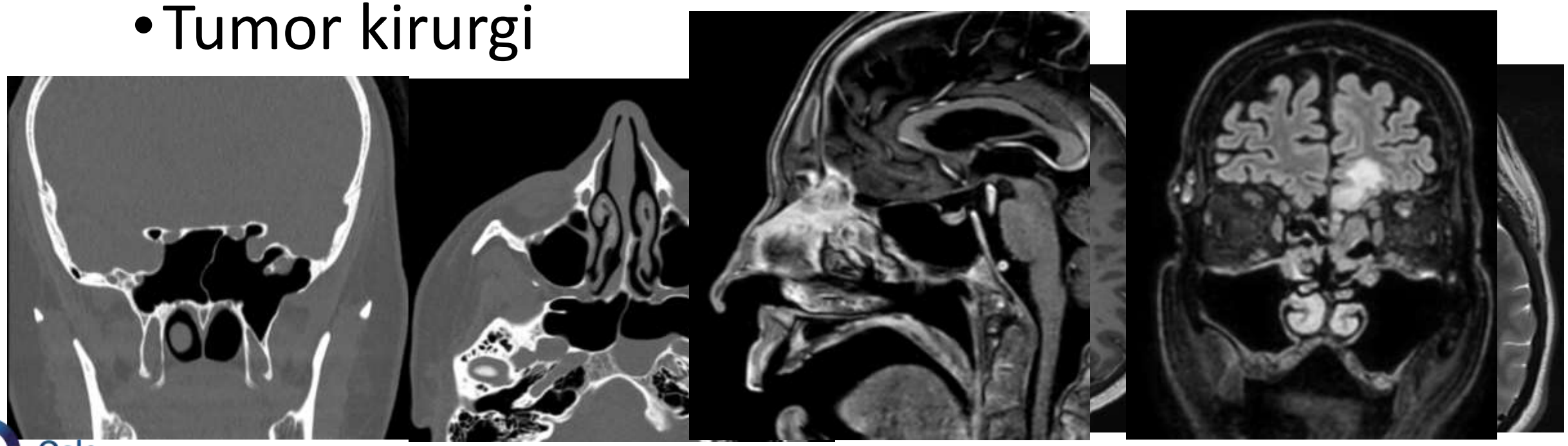

Oslo universitetssykehus

3 trinn kirurgi

- Tilgang
- Reseksjon
- Lukking / Rekonstruksjon

Kirurgisk tilgang

- Endoskopisk
- Åpen
- Kombinasjon

- Valg av tilgang:
  - Pasient: Alder, co-morbiditet
  - Tumor: Lokalisasjon, størrelse, og histopatologi
  - Kirurgerfaring

Endoskopisk tilgang

Sagitalplan plane

- Transfrontal
- Transcribriform
- Transplanum
- Transsellar
- Transclivial
- Transodontoid

Koronal plane

- Anterior
  - Supraorbital
  - Transorbital
- Middle
  - Medial
  - Suprapetrous
  - Infratemporal
- Posterior
  - Transcondylar
  - Infrapetrous
  - Parafaryngeal

Solitær fibrøs tumor

- 54 år
- Tett nese
- Epistaxis

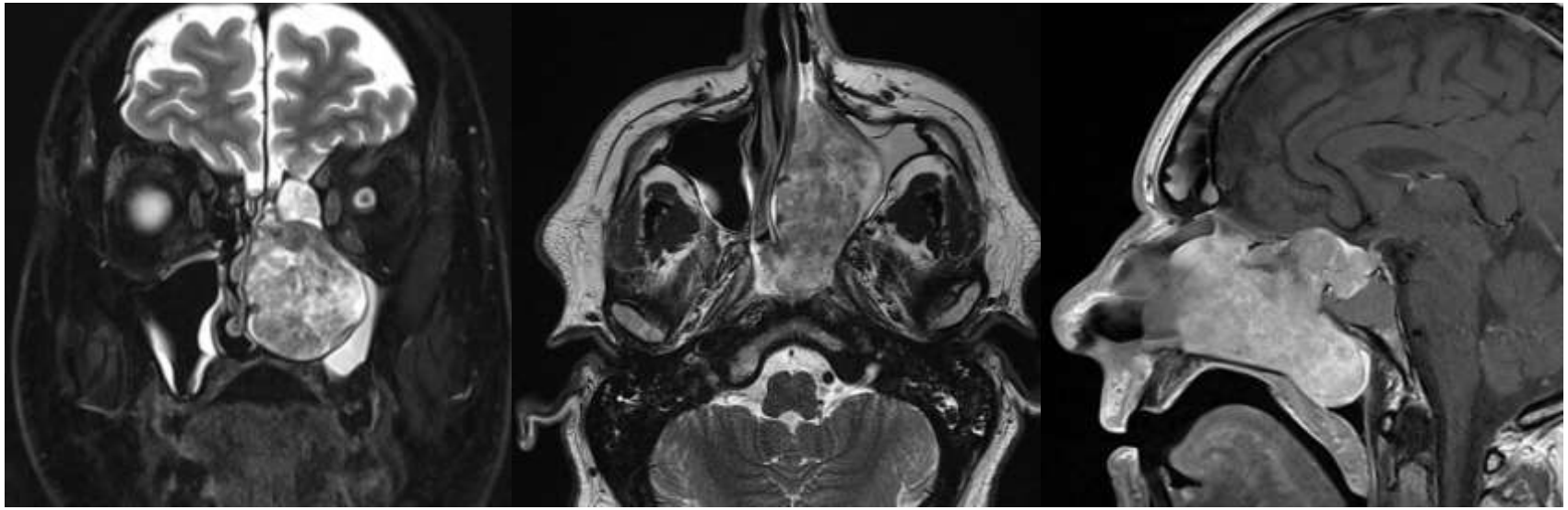

- Endoskopisk
- Fjerning

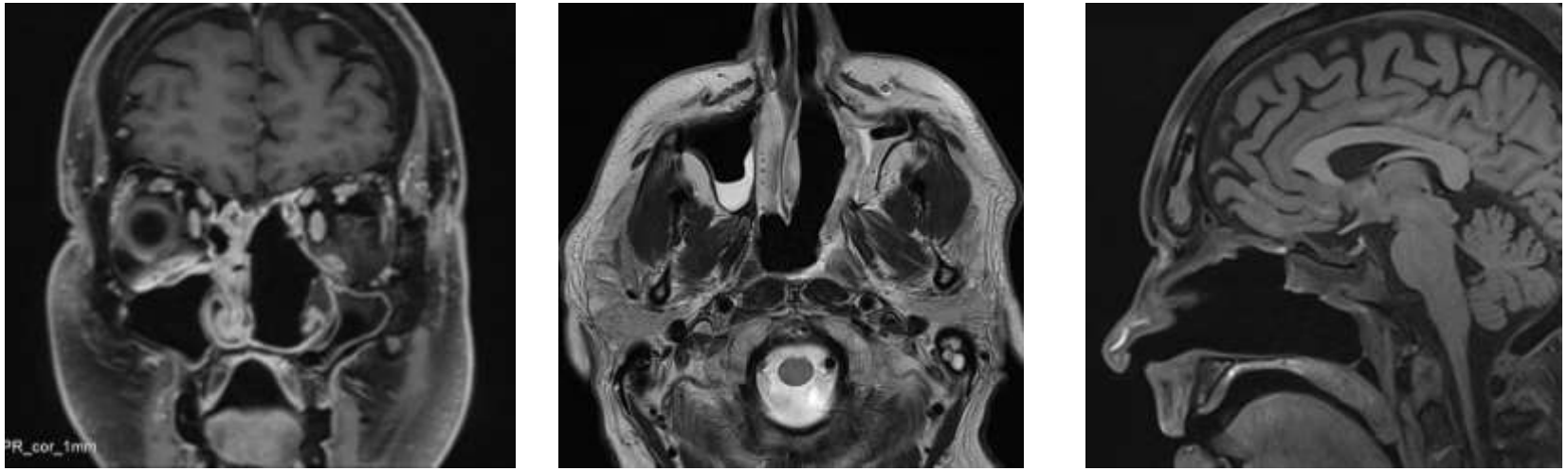

Åpen tilgang

- Sublabial tilgang
- (Midfacial degloving)

Midfacial degloving -kasuistikk

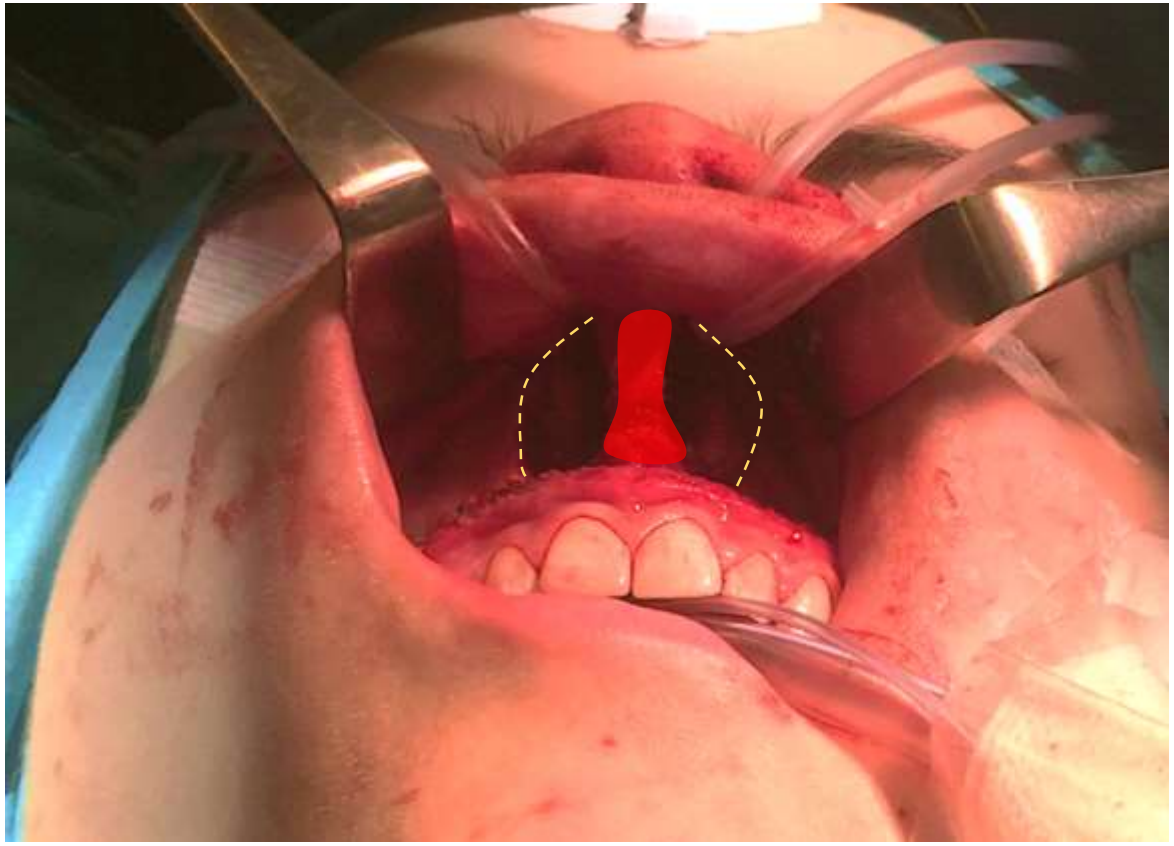

Midfacial degloving -kasuistikk

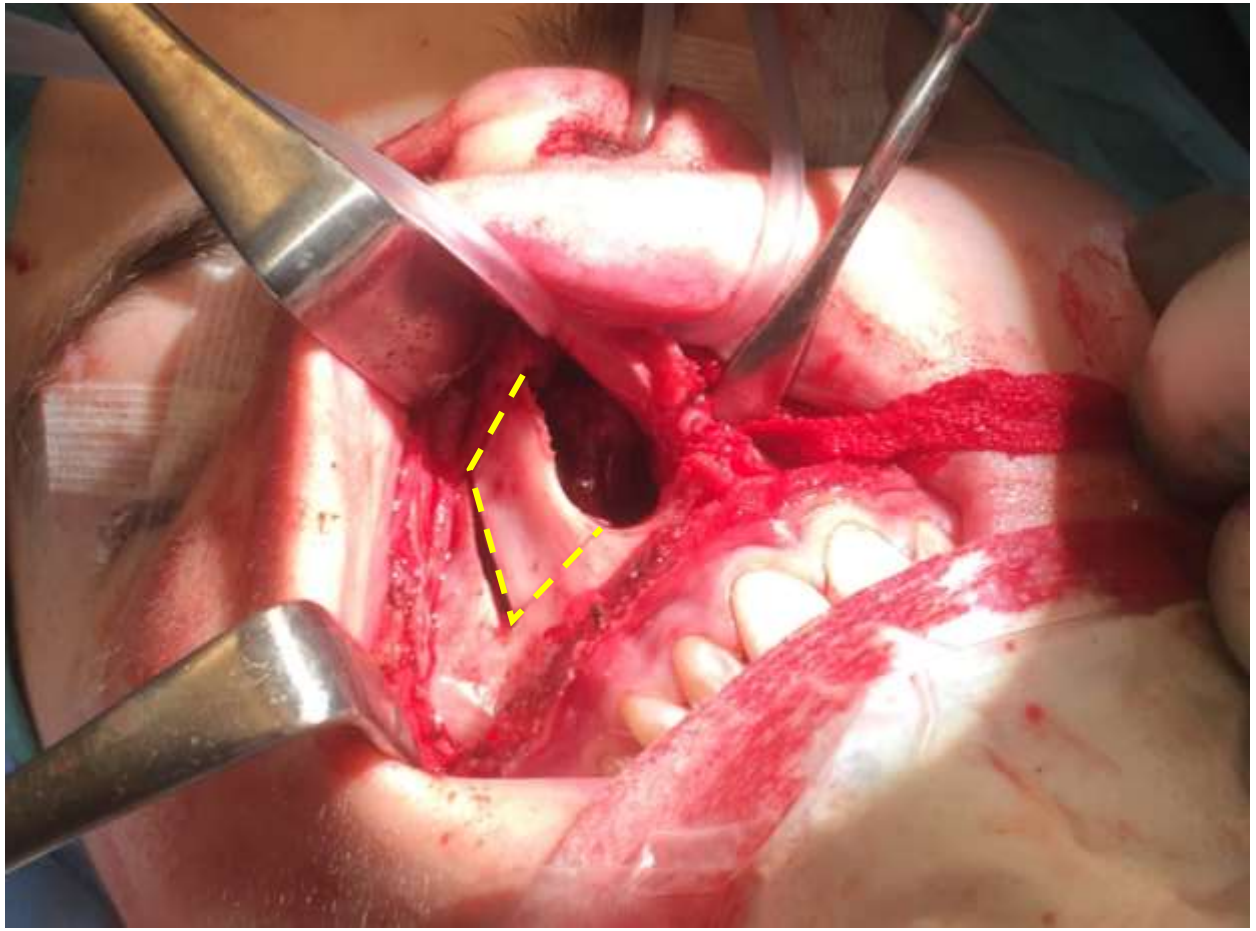

Midfacial degloving -kasuistikk

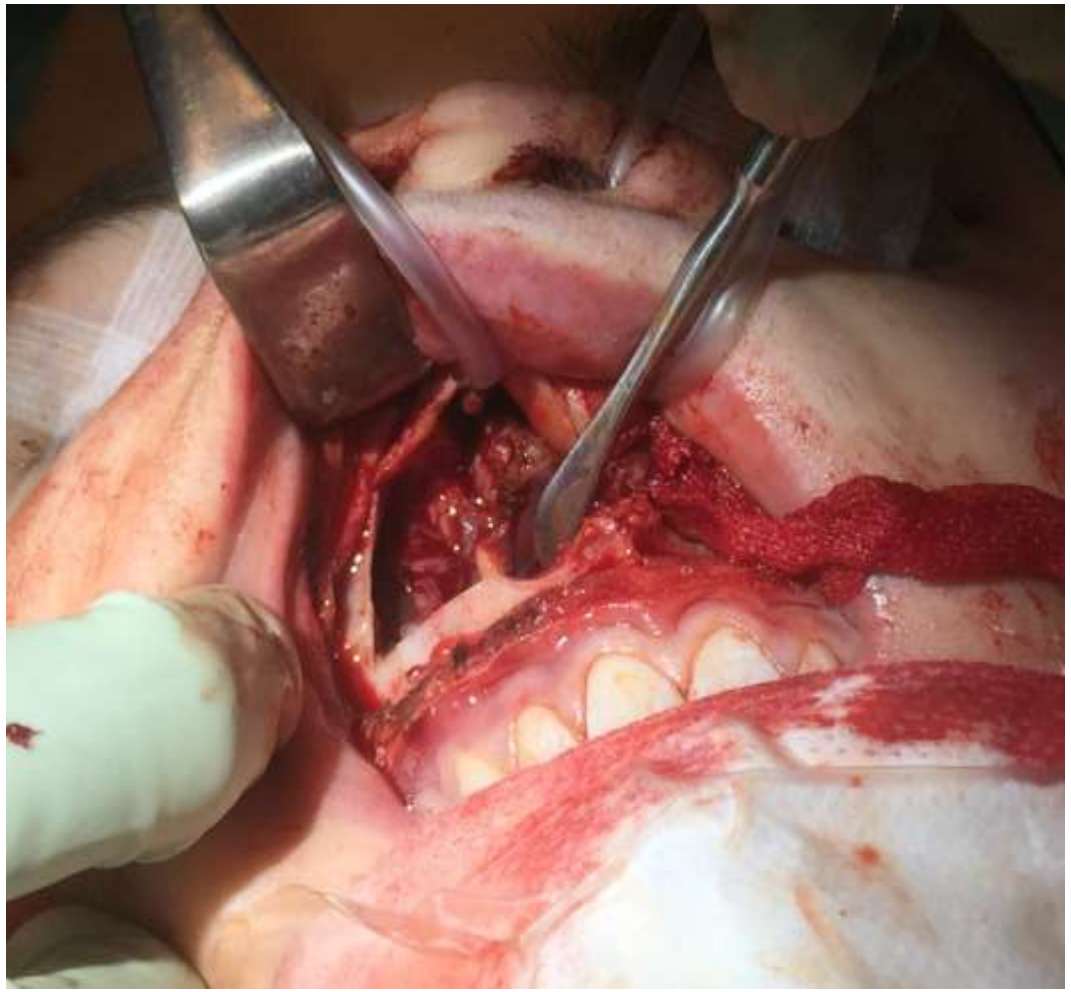

Fjerning av JNA via sublabial tilgang

- 11 år gutt
- Nasal stenose og epistaxis

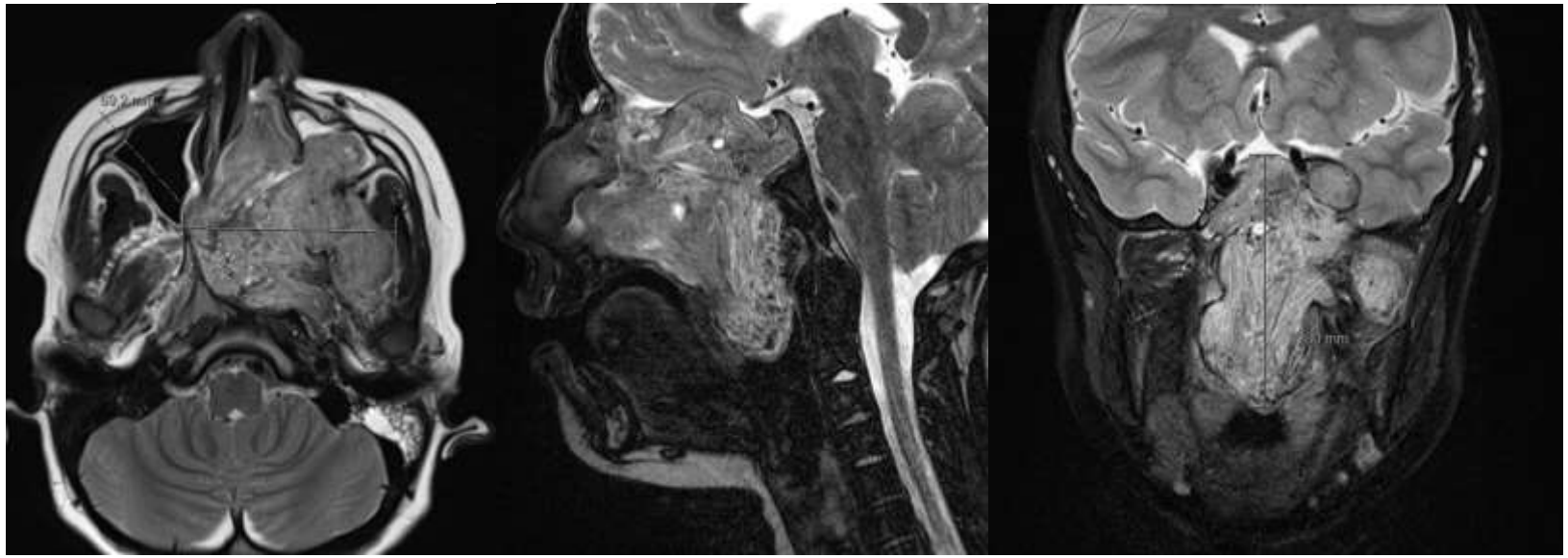

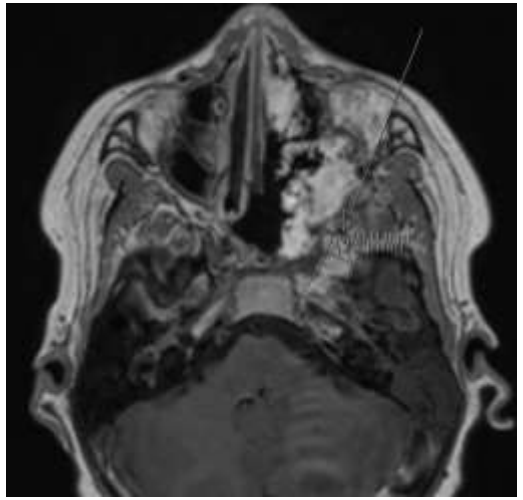

Åpen tilgang

- Lateral rhinotomi

Lateral Rhinotomi -kasuistikk

Lateral Rhinotomi -kasuistikk

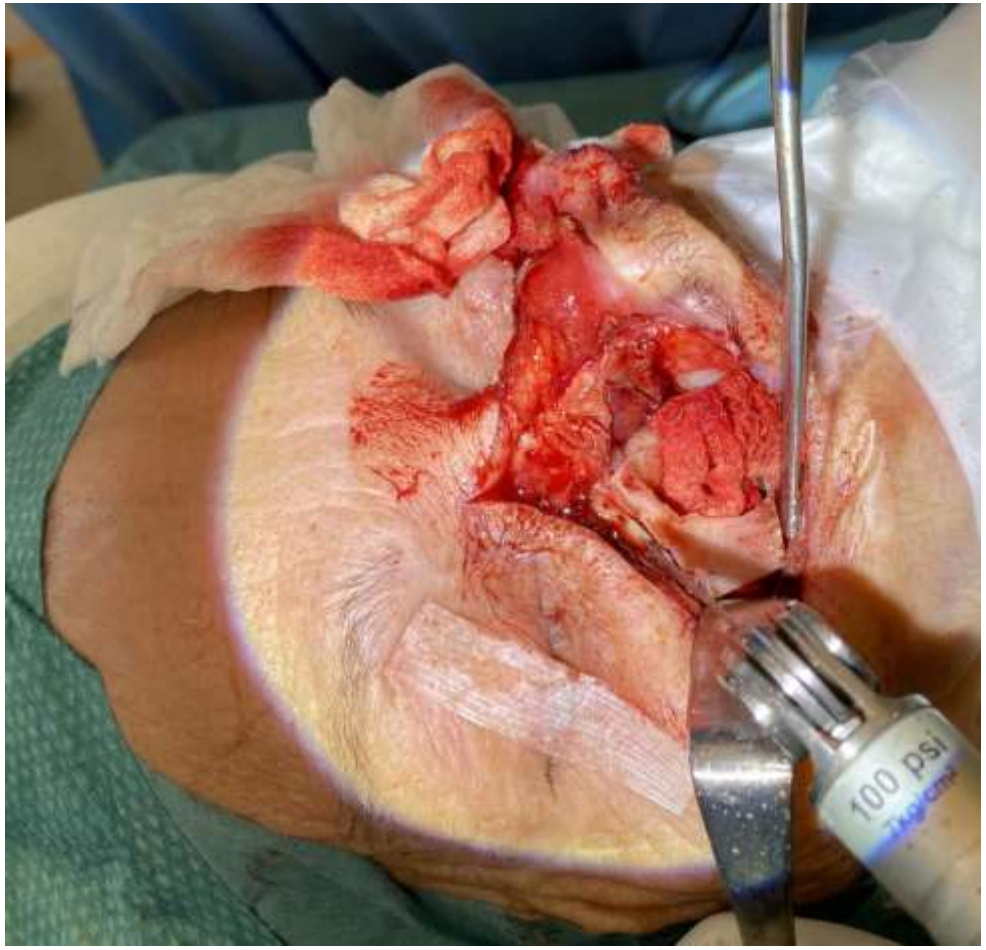

saging

Lateral Rhinotomi -kasuistikk

Lateral Rhinotomi -kasuistikk

Tamponerer og lukker i 2 lag

Åpen tilgang

- Weber-Ferguson tilgang

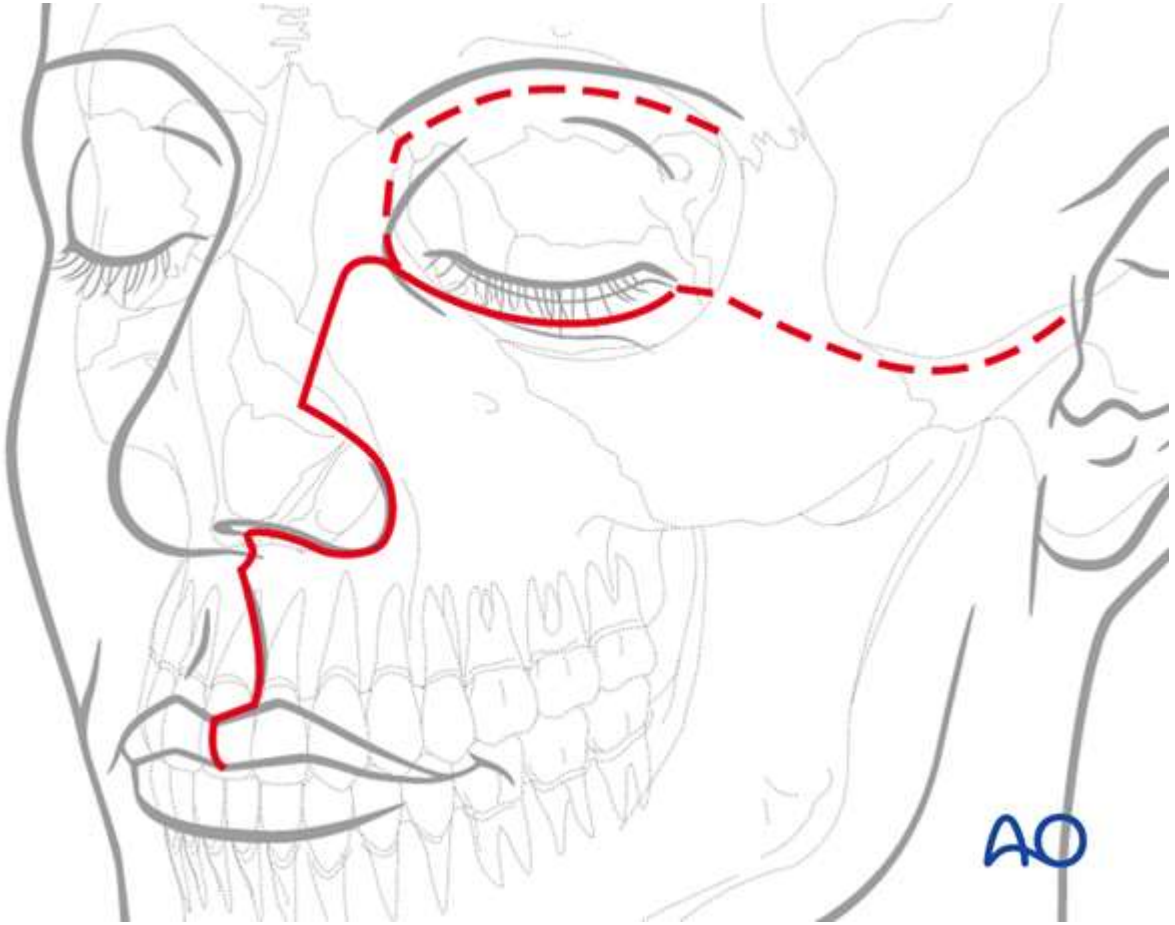

Åpen tilgang

- Craniofasial reseksjon: (Lateral rhinotomi + craniotomi)

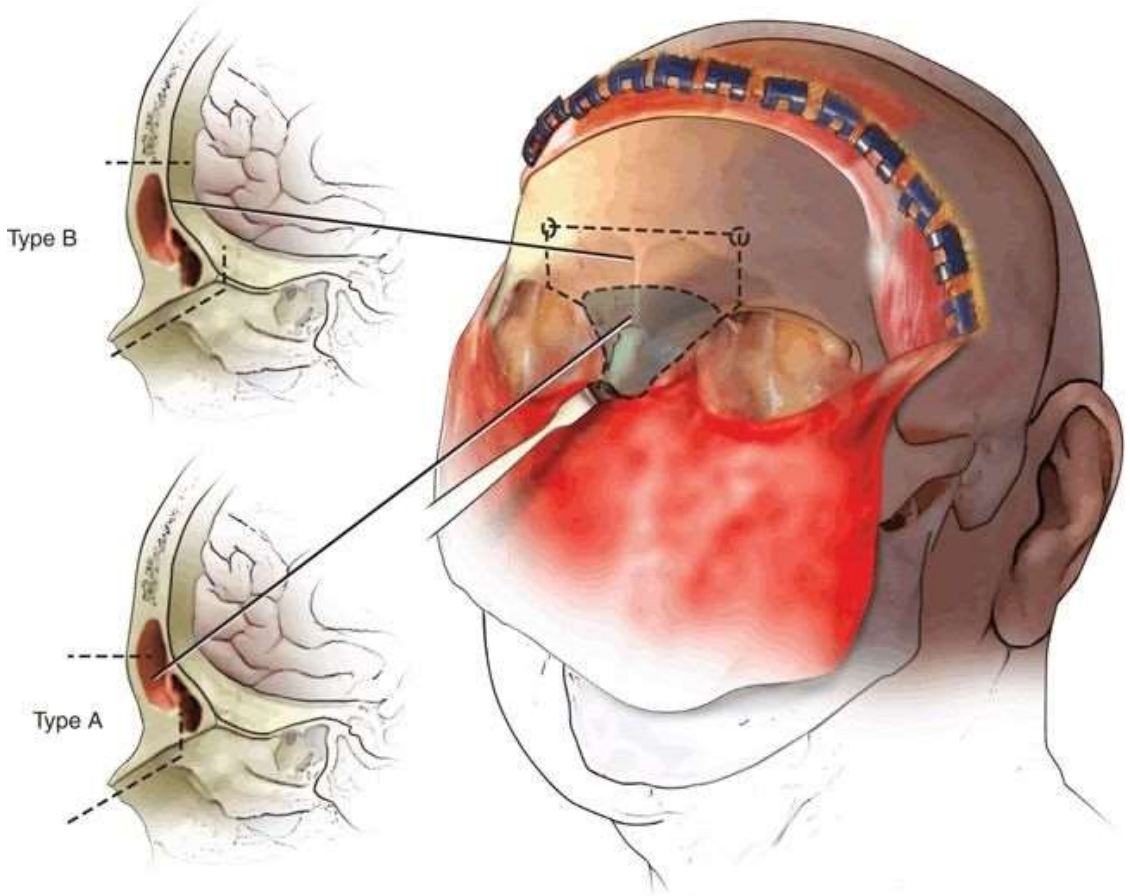

Oslo universitetssykehus

Kombinert tilgang

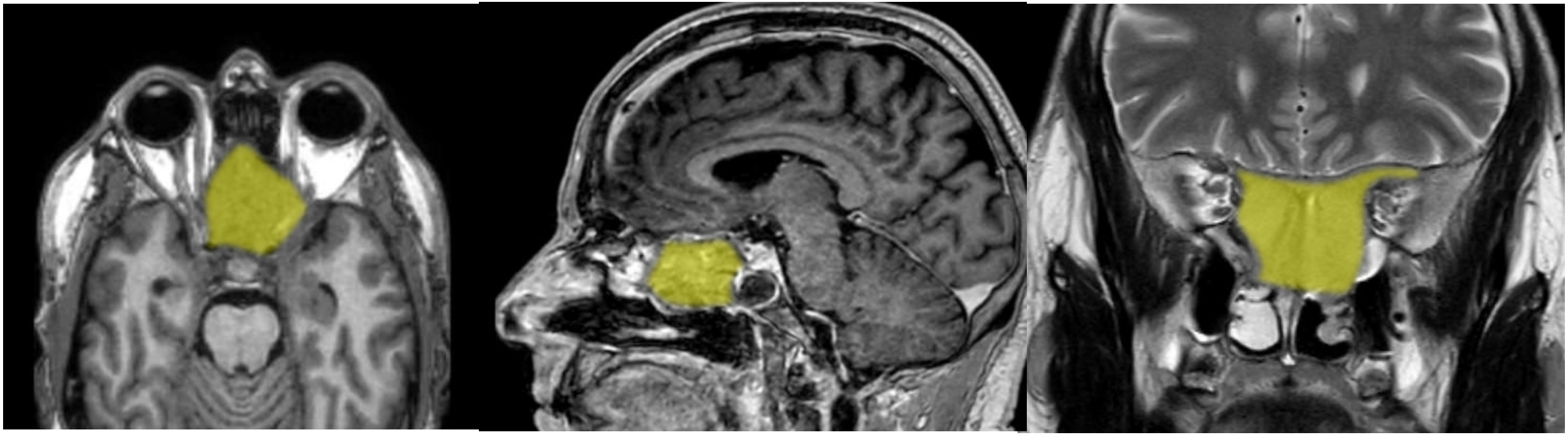

Kombinert tilgang

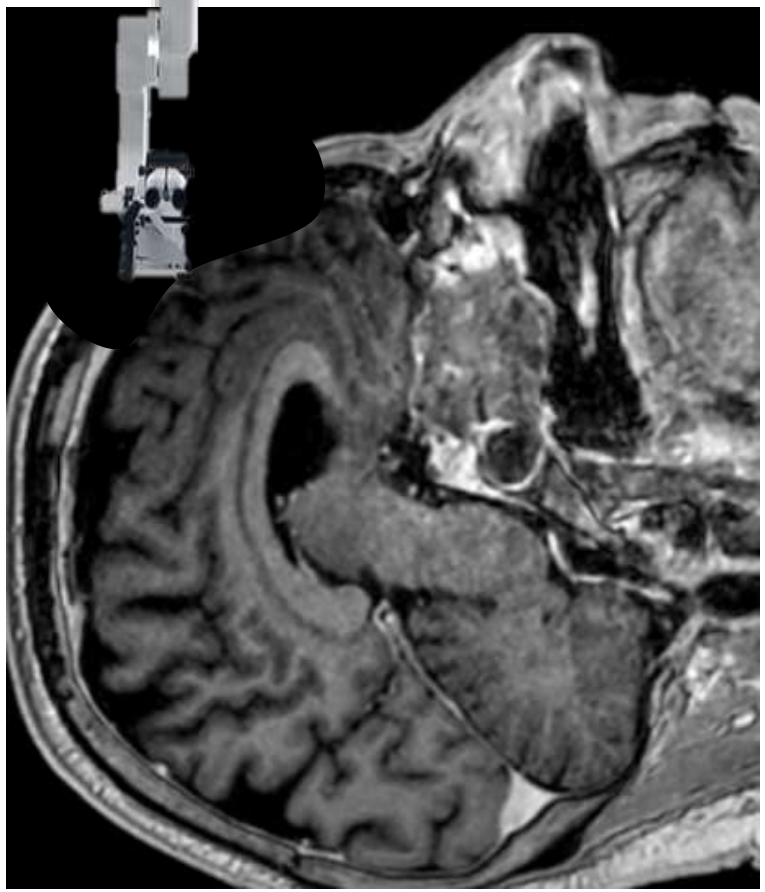

Kombinert tilgang

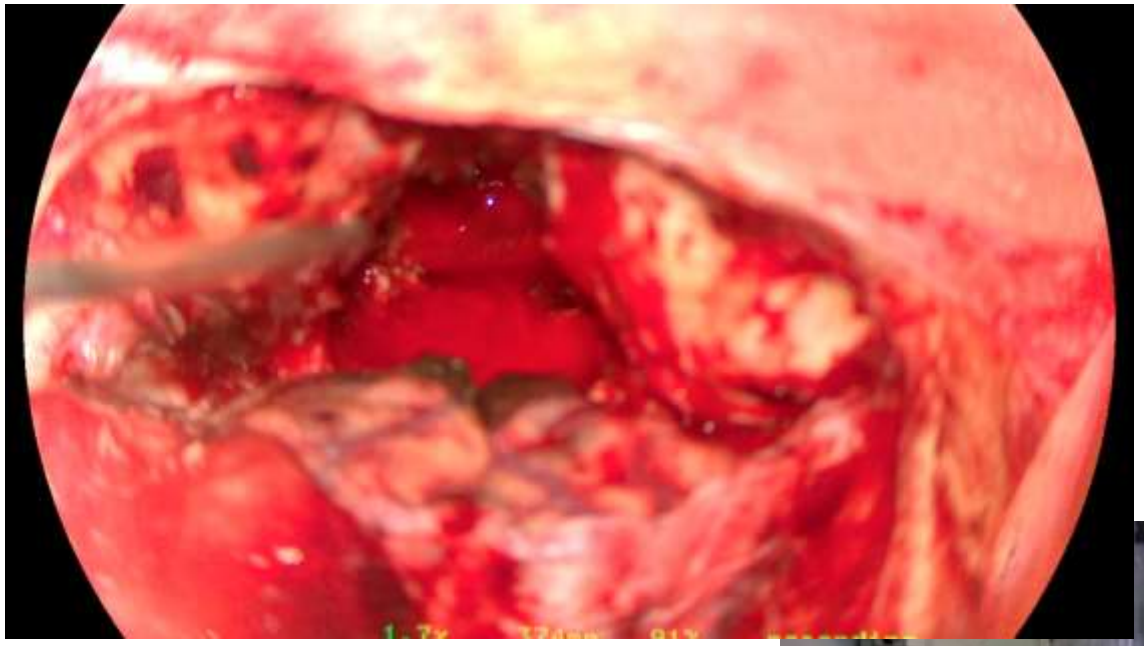

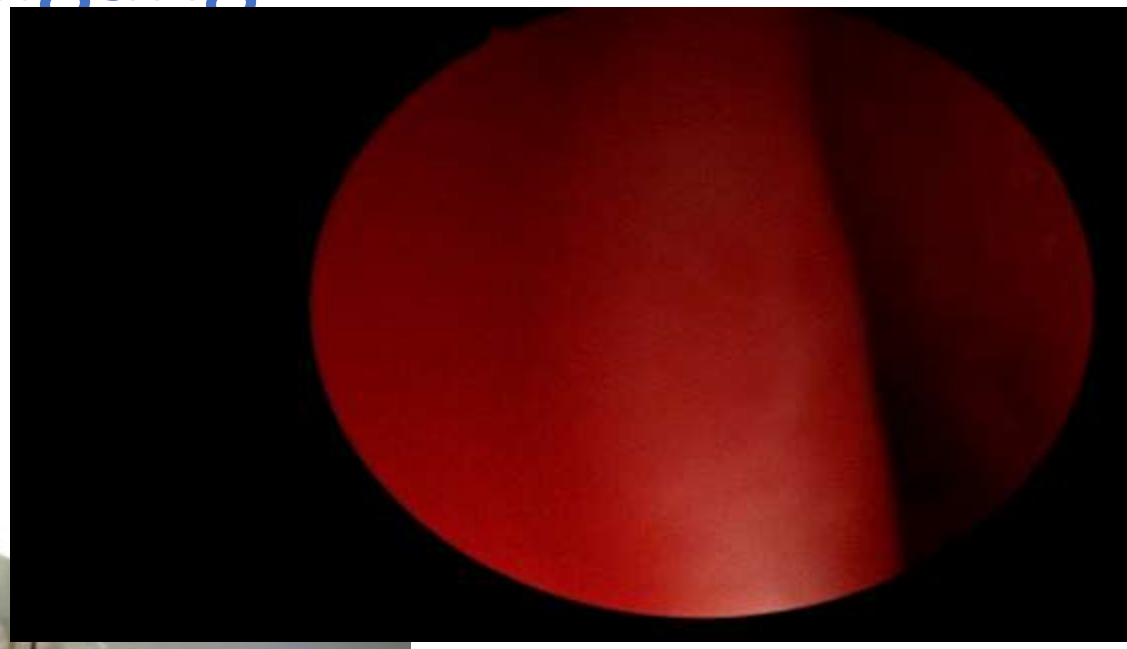

Kombinert tilgang

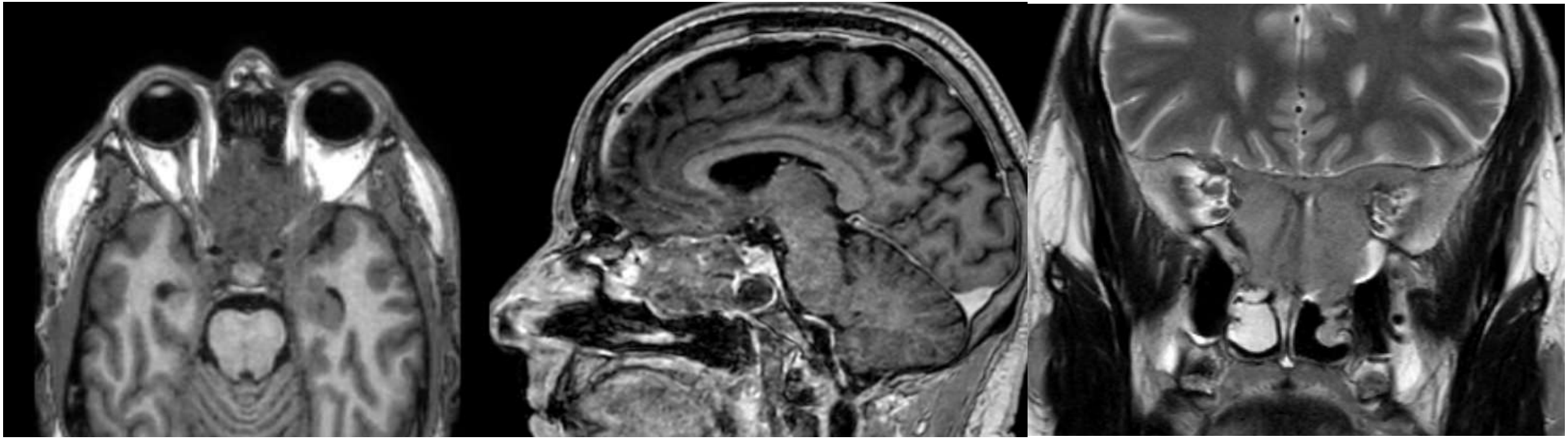

Kombinert tilgang

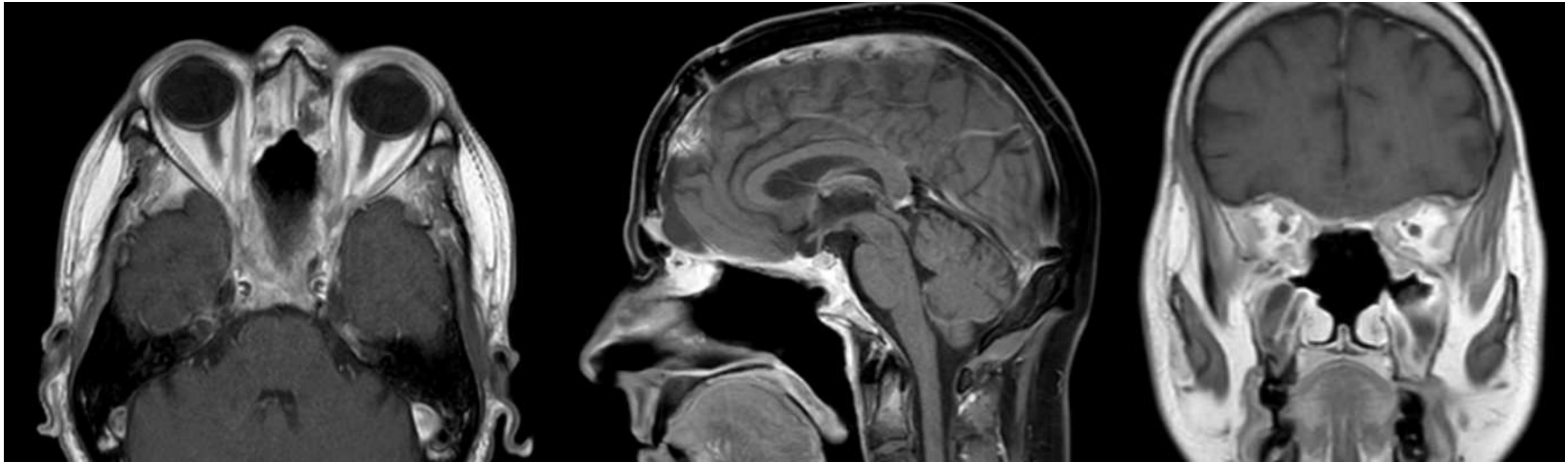

Lukking / Tetting/ Skallebasis rekonstruksjon

- Avhengig av
  - Størrelse
  - Lokalisasjon
  - Tilgjengelig vev

Pericranium lap

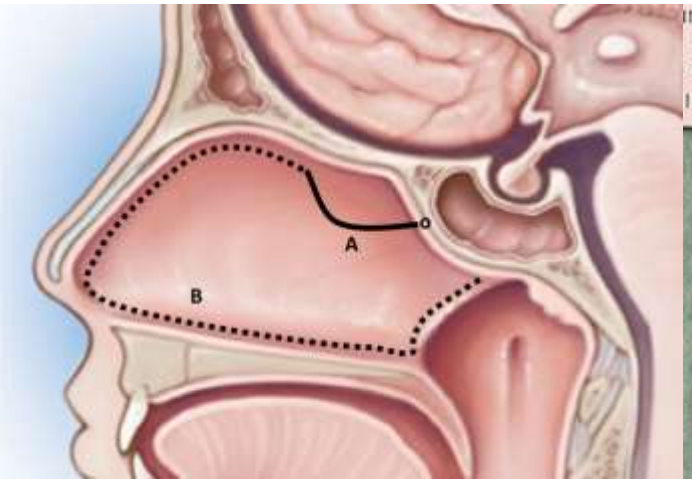

Nasoseptal lap

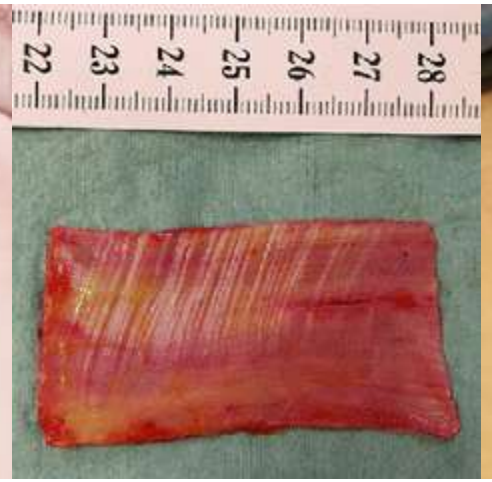

Facia lata graft

Abdominal fett

Lukking / Tetting/ Skallebasis rekonstruksjon

- Avhengig av
  - Størrelse
  - Lokalisasjon
  - Tilgjengelig vev
  - Kunstig materiale

DuraGen

Tachosil

Eksemlpler

Lamina cribrosa meningocele

- 65 år dame
- CSF rhinorrhe
- CT: Lamina cribrosa meningocele

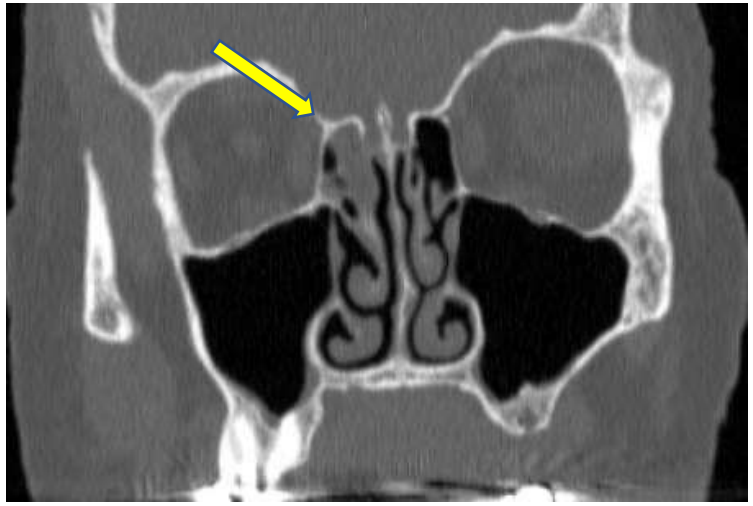

- Tettet endoskopisk med concha media lapp

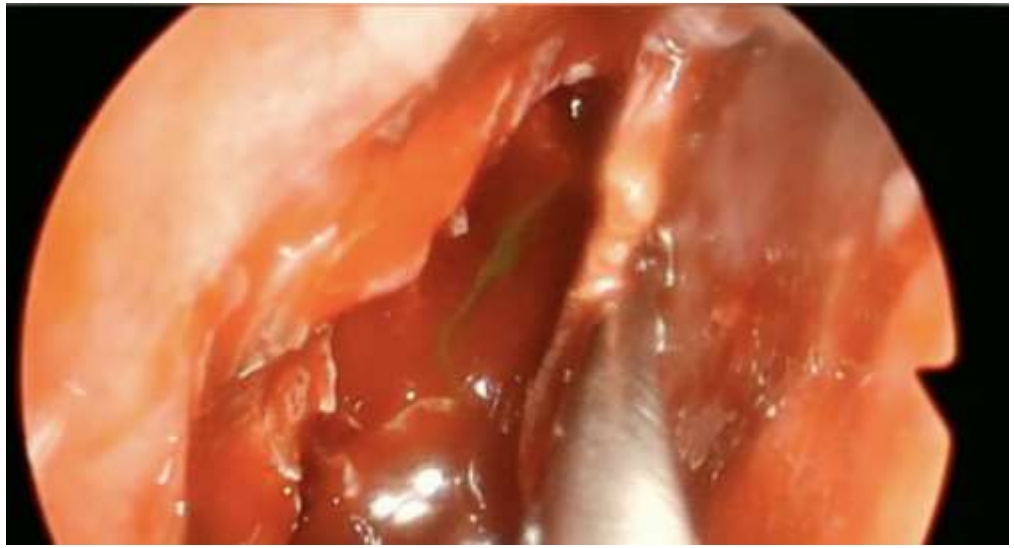

Oslo universitetssykehus

Sternberg´s kanal CSF lekkasje

- CSF rhinorhe
- CT: stor sfenoidal sinus, 2 defekt i lateral recess Meningocele?
- MR: n.opticus ødem og dilatert ventrikkelsystem

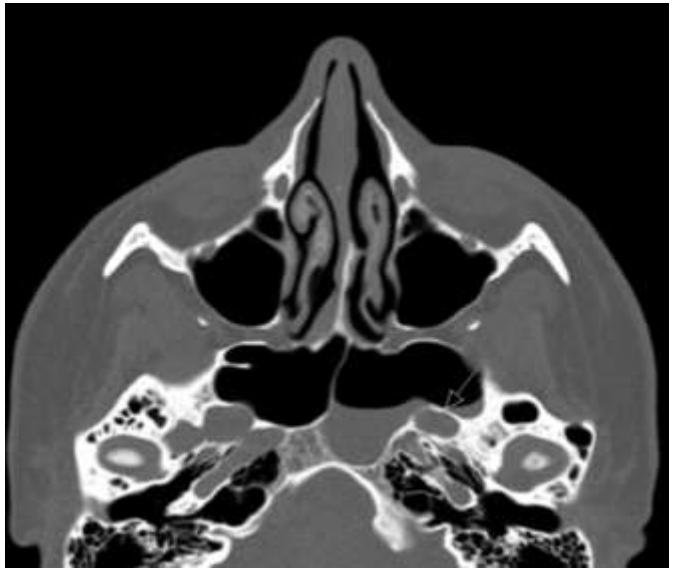
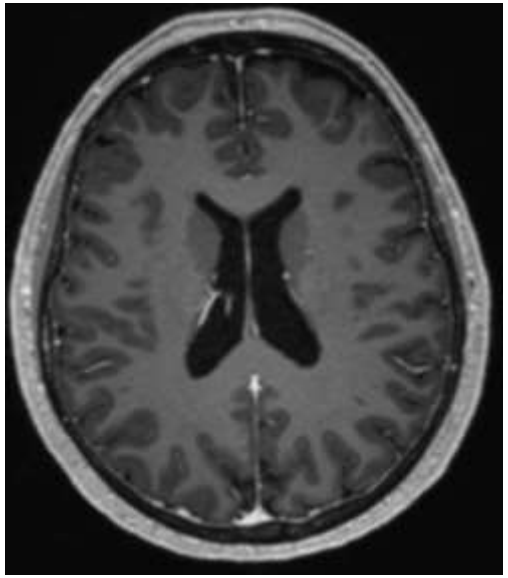
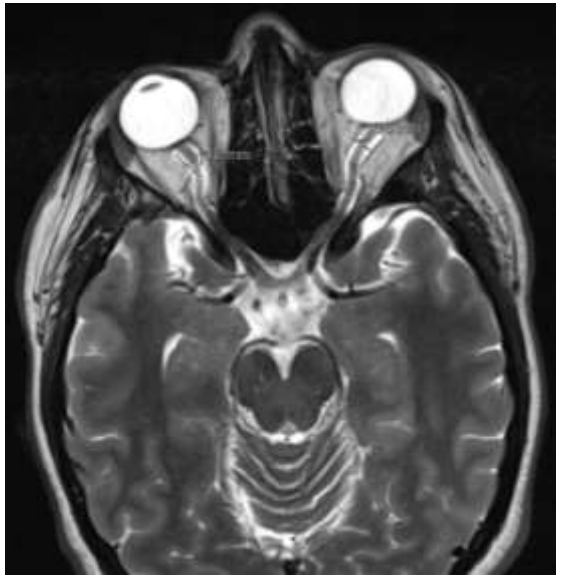

Sternberg´s kanal CSF lekkasje

- Endoskopisk transptyregoid tetting + VP shunt

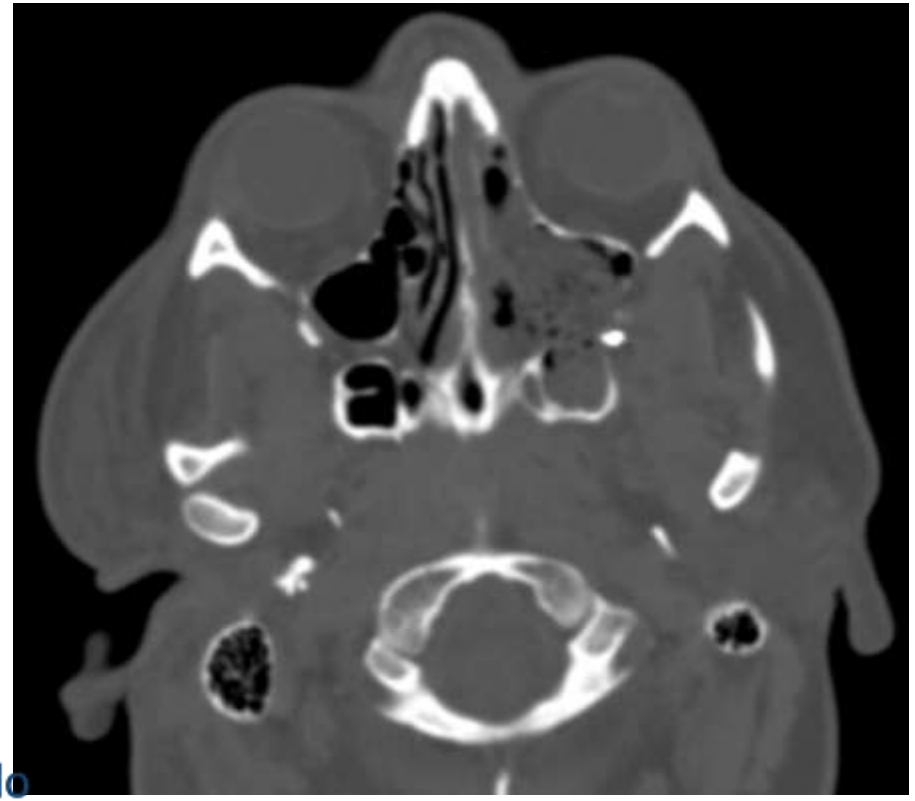

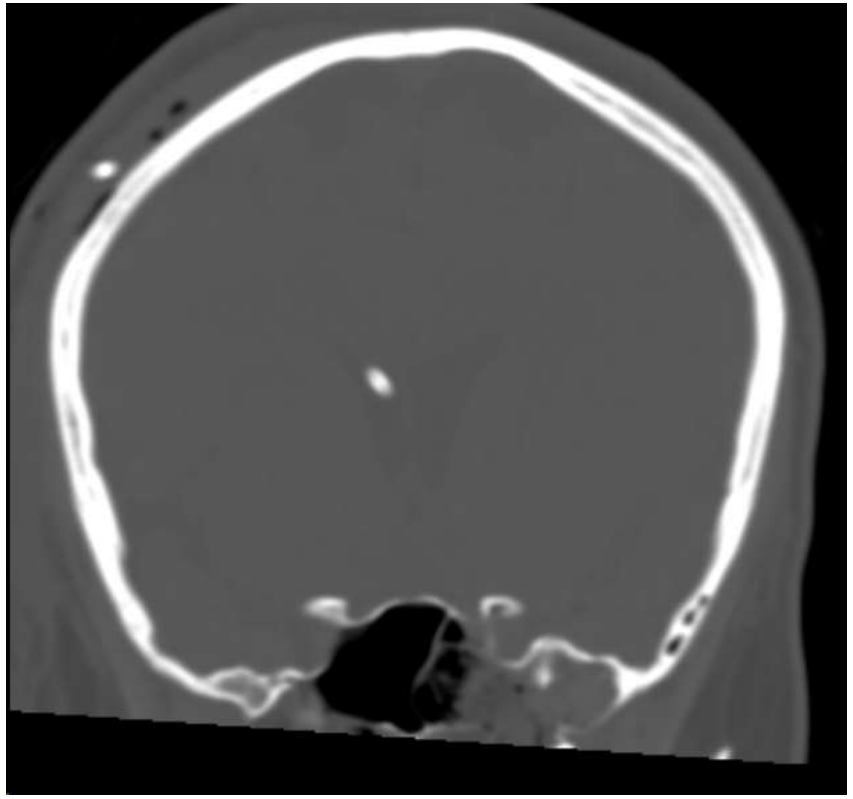

Oslo universitetssykehus

Endoskopisk fjerning av tumor

- 4 hender

Solitær fibrøs tumor

- 54 år, tett i nesen med blødning

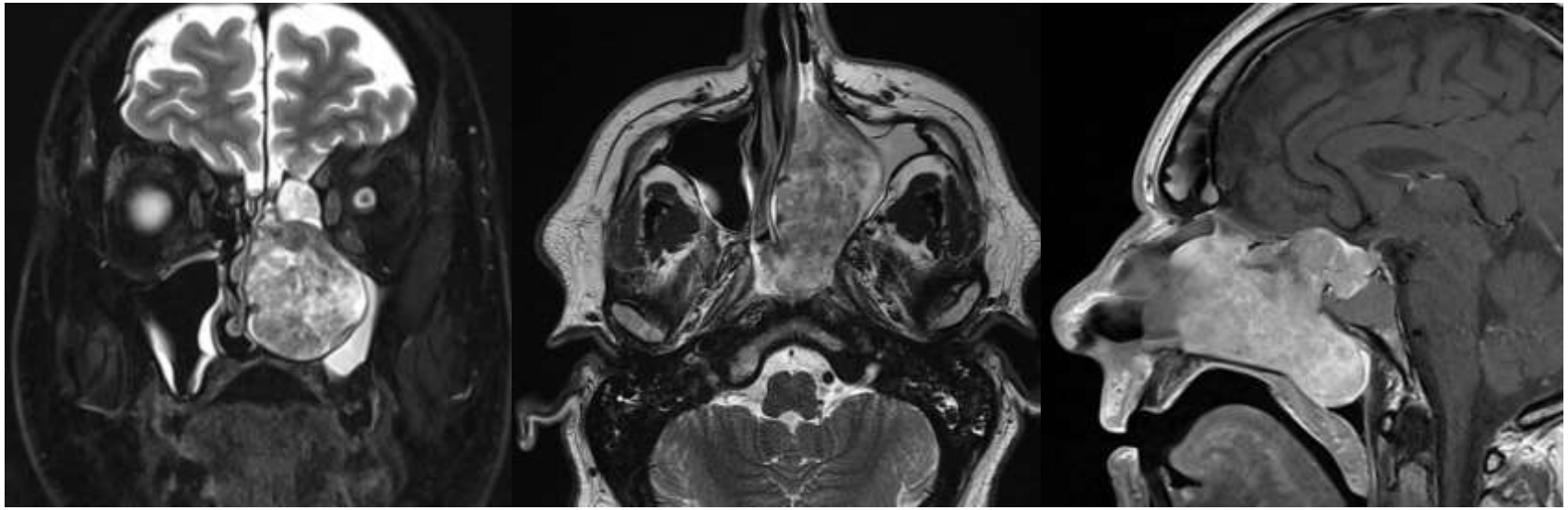

- Endoskopisk fjerning

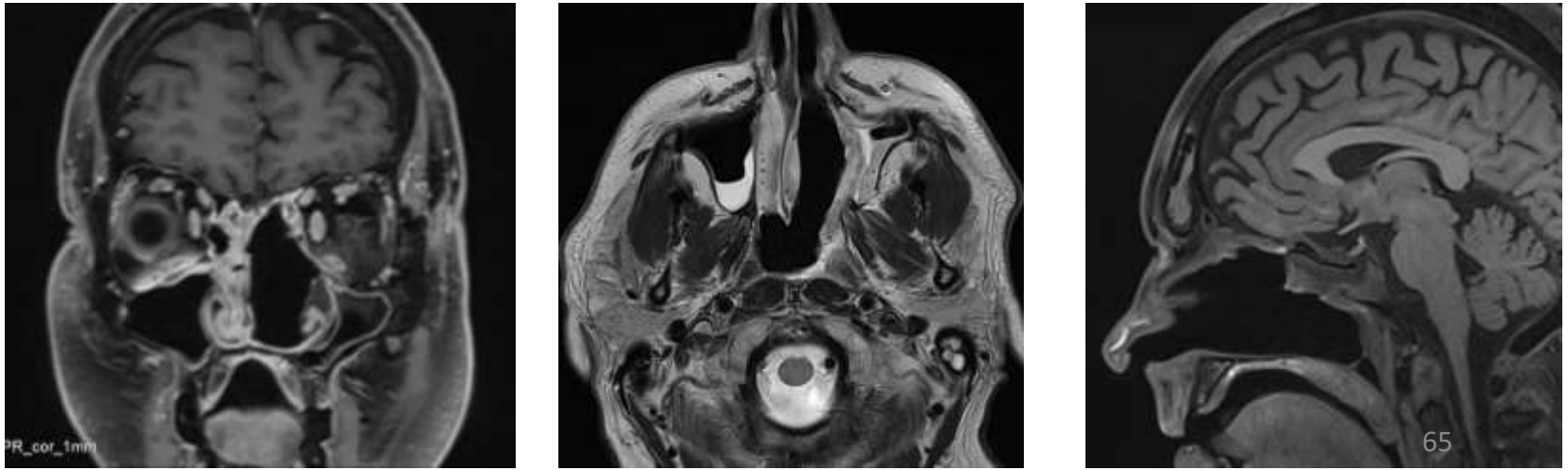

Oslo universitetssykehus

Symptom lindrende debulking

Endoskopisk debulking (Symptom lindrende)

- Malign tumor ?

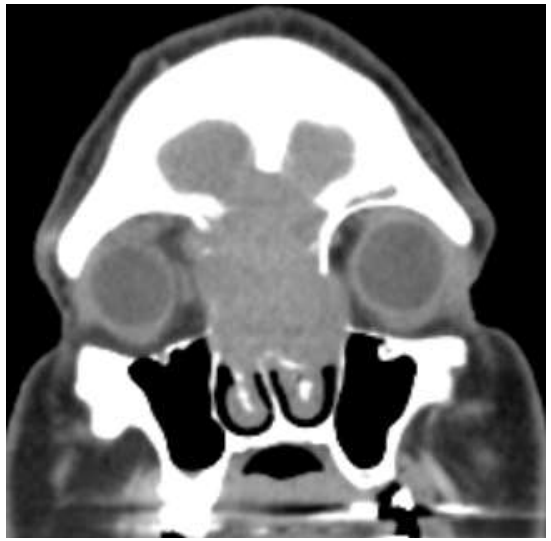

Endoskopisk debulking (Symptom lindrende)

- Malign tumor ?

- 2,5 år etter endoskopisk debulking

Oslo universitetssykehus

Craniofasial reseksjon

Esthesionevroblastom

- 27 år ♂.
- Tett i nesen og redusert syn

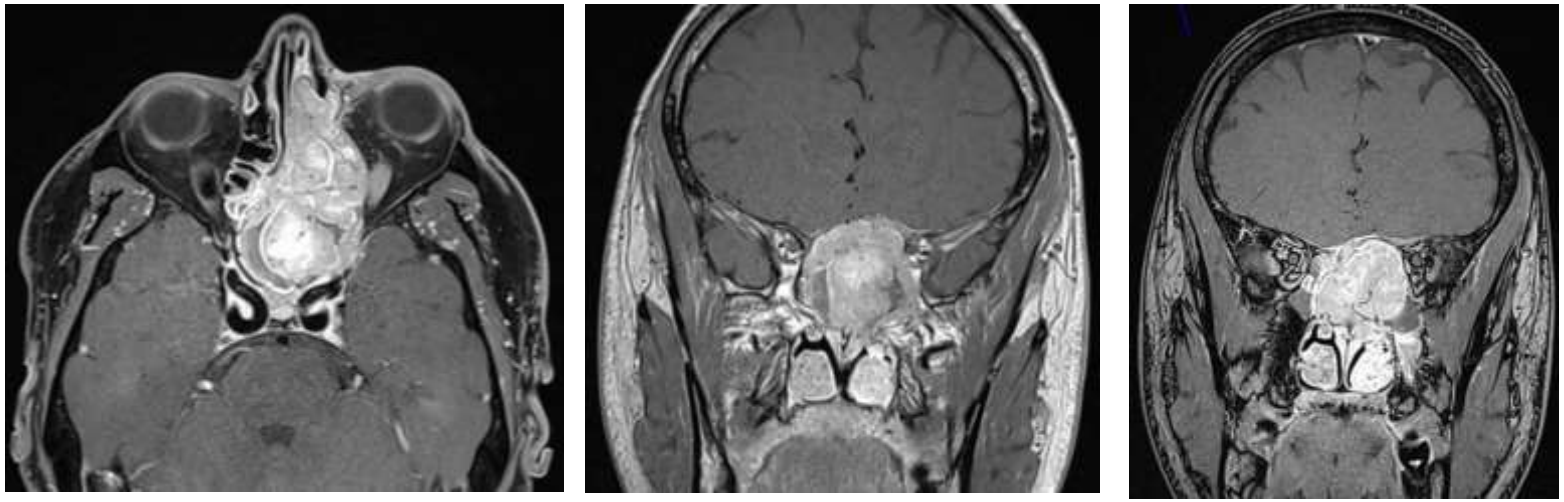

Esthesionevroblastom

- 27 år ♂.
- Tett i nesen og redusert syn

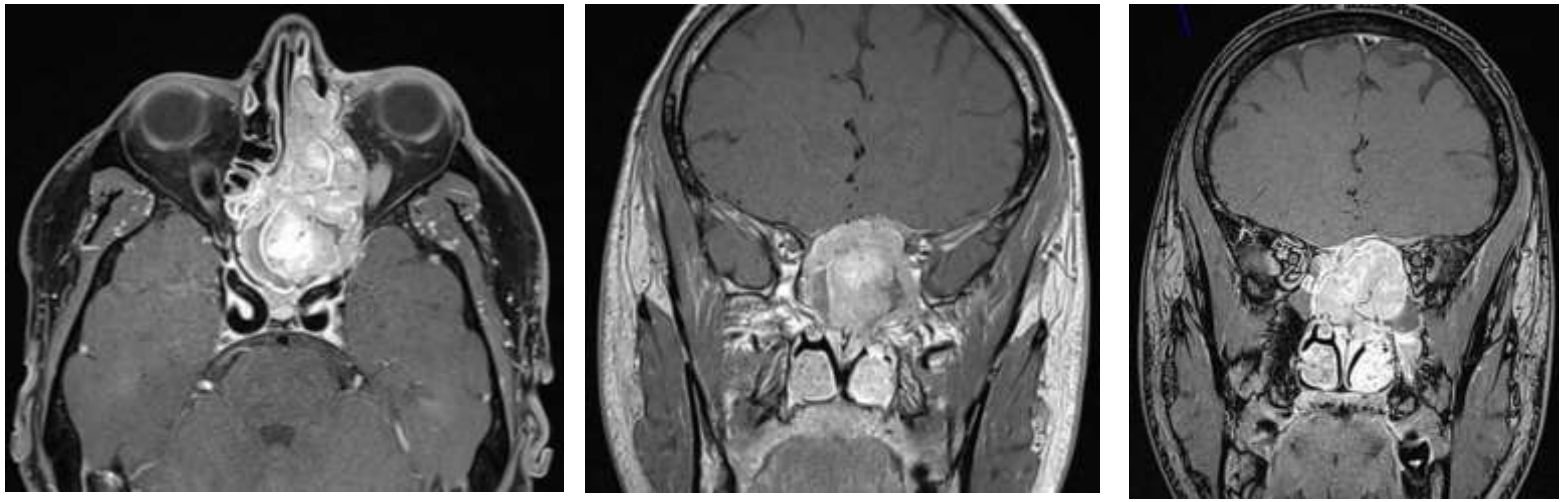

- Craniofasial reseksjon

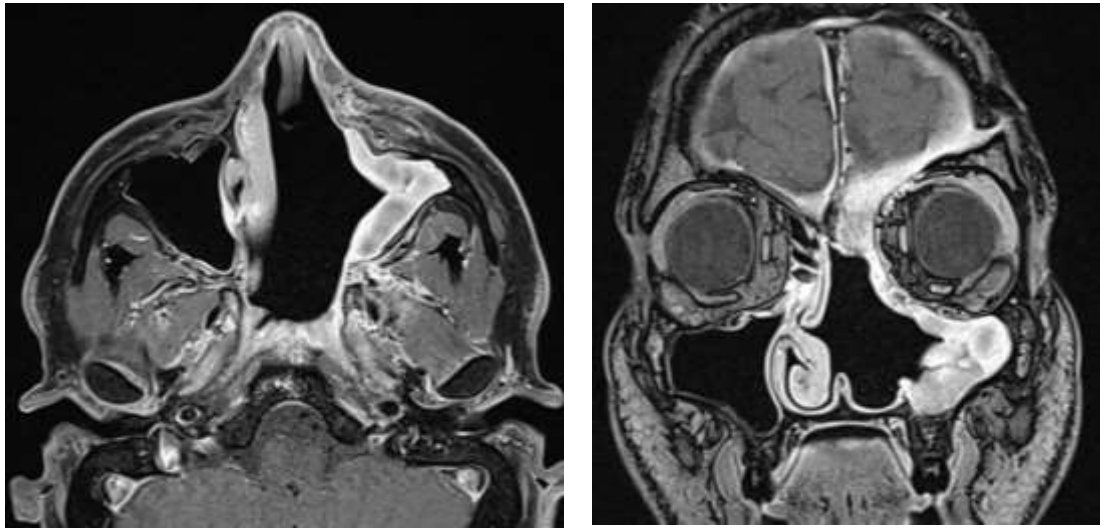

Oslo universitetssykehus

Esthesionevroblastom

- 8 mnd senere:
  Rest i fossa ptyregopalatina

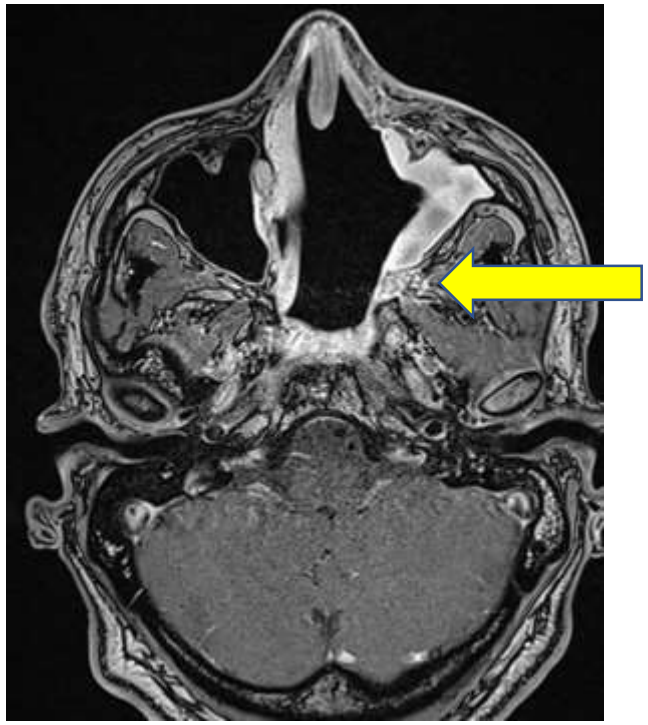

- Fjernet endoskopisk

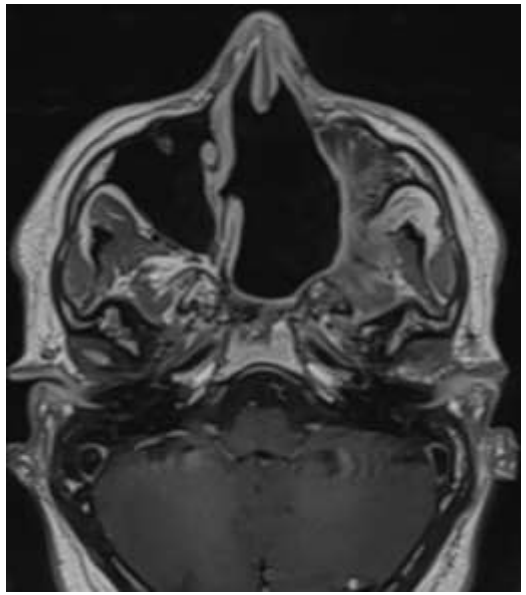

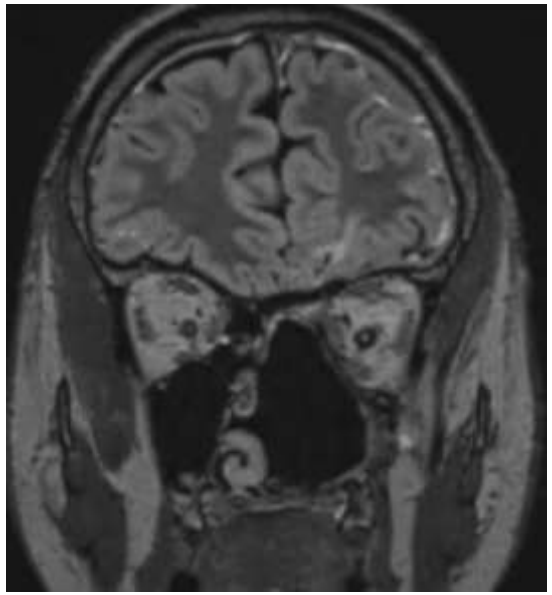

Oslo universitetssykehus

Kombinert tilgang

- Endoskopisk + mini- craniotomi

Kombinert tilgang

- 44 år gammel kvinne
- 5 dager hodepine, akutt blindhet på hø side

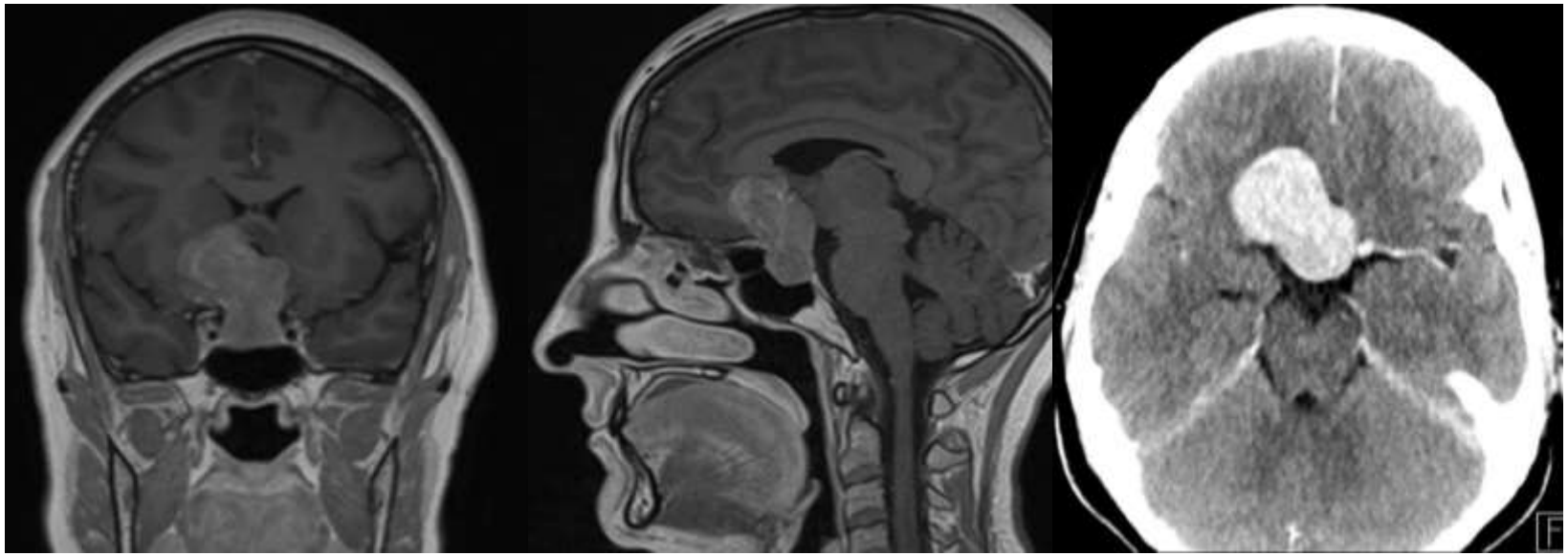

Kombinert tilgang

- 44 år gammel kvinne
- 5 dager hodepine, akutt blindhet på hø side

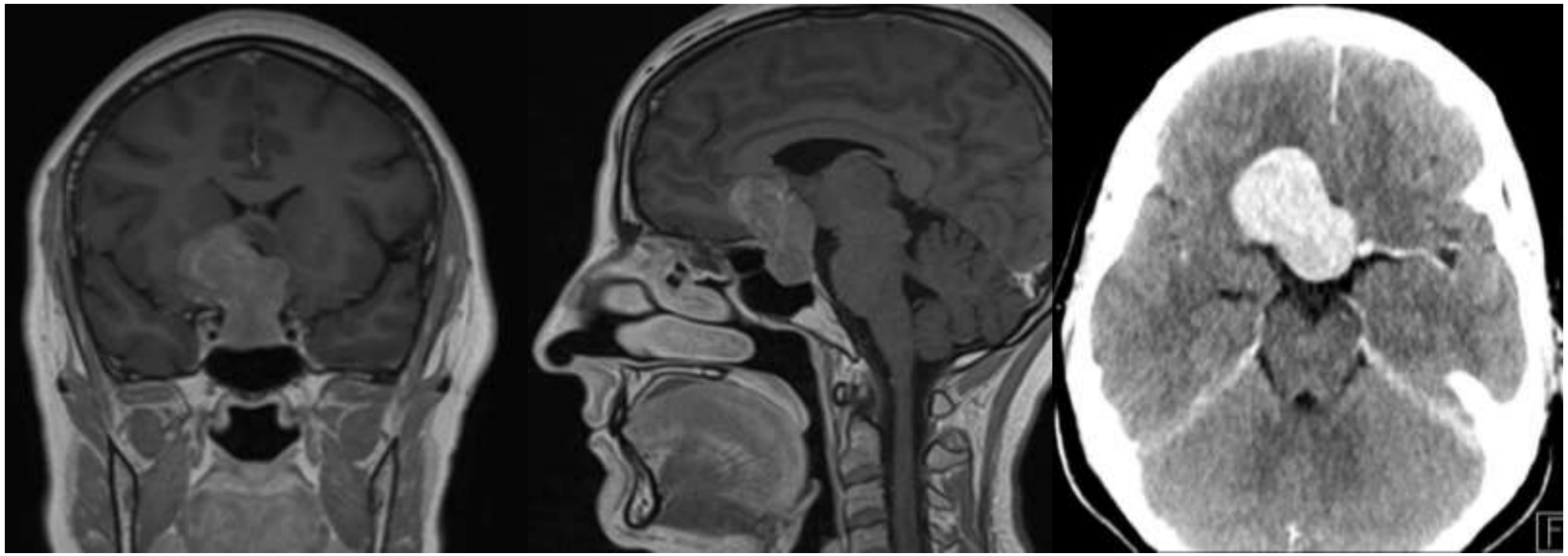

- Ø.hjelp kirurgi:
- Kombinert tilgang: Endoskopisk med mini-craniotomi

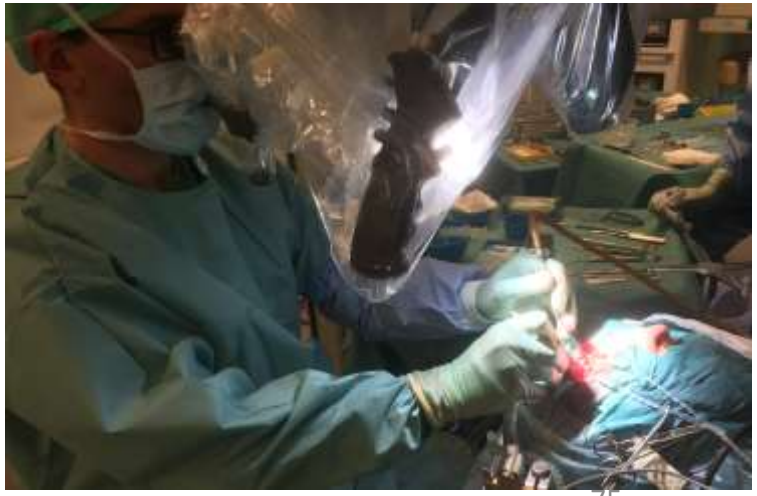

Oslo universitetssykehus

Kombinert tilgang

- 44 år gammel kvinne
- 5 dager hodepine, akutt blindhet på hø side

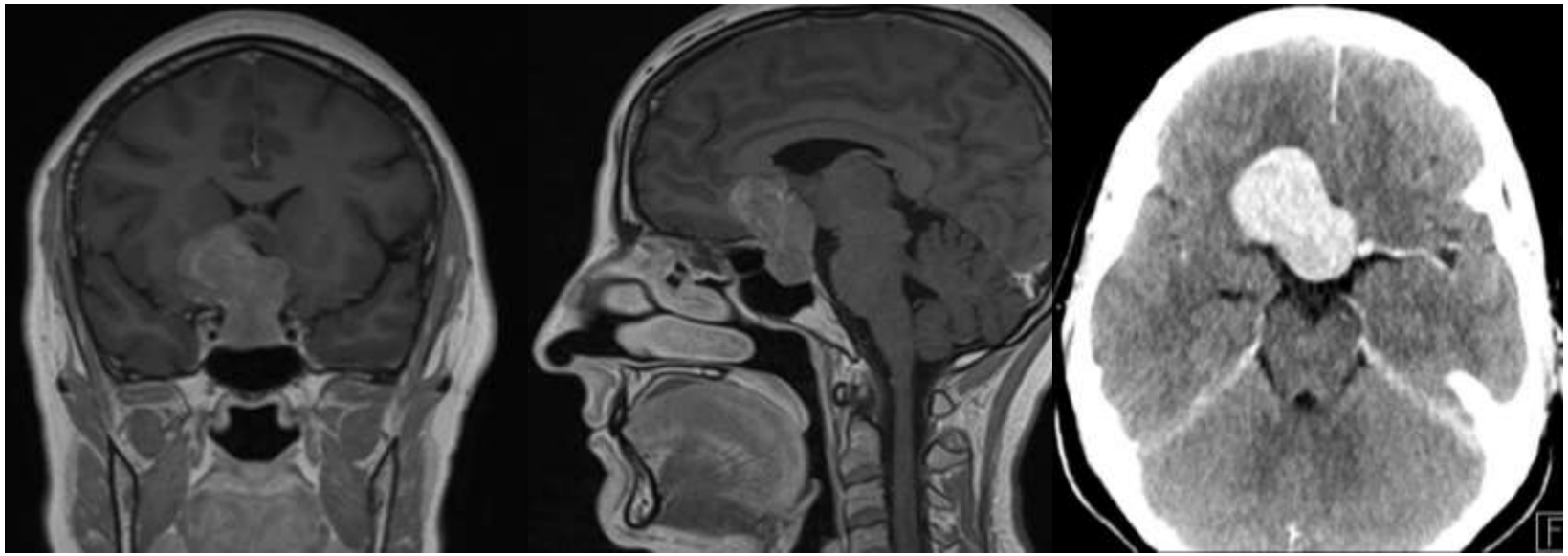

- Ø.hjelp kirurgi:
- Kombinert tilgang: Endoskopisk med mini-craniotomi

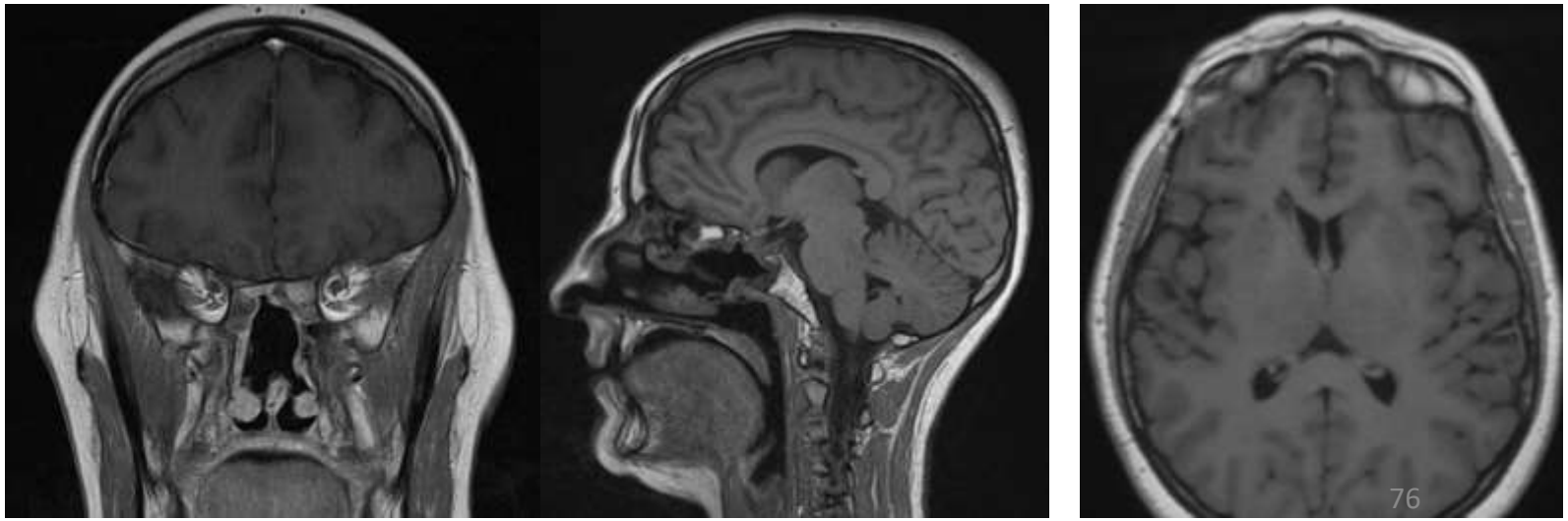

Oslo universitetssykehus

Juvenilt nasofarynks angiofibrom

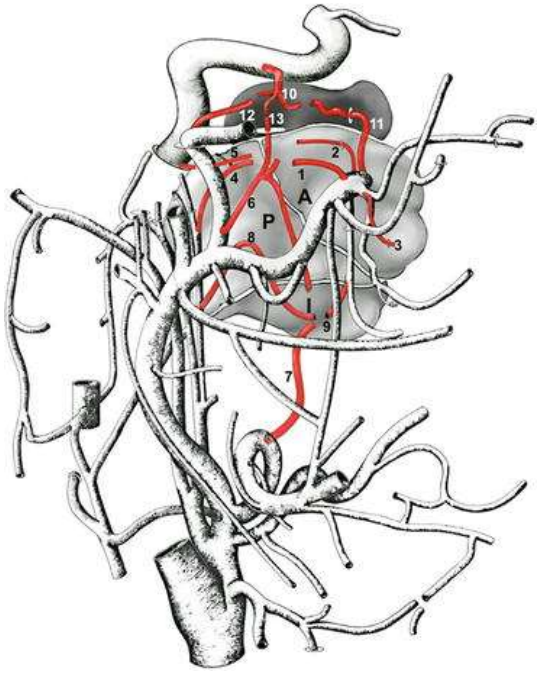

Oslo universitetssykehus

Endoskopisk fjerning av JAN

- 20 år gutt
- 2 år nasal stenose
- Ingen blødning

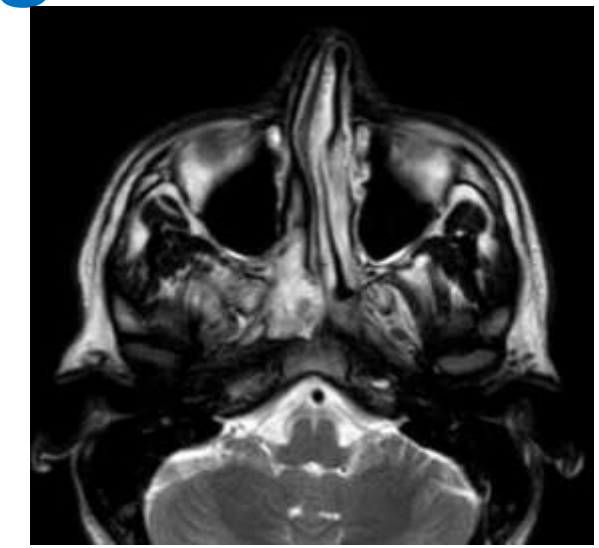

- Endoskopisk fjerning
- uten coiling

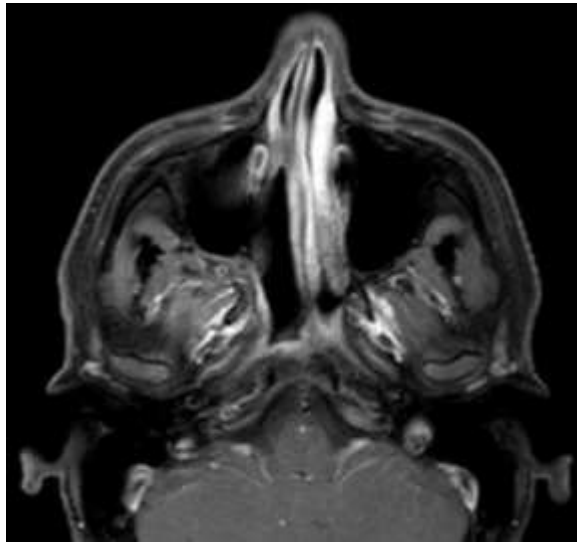

Oslo universitetssykehus

Fjerning av JAN med sublabial tilgang

- 11 år gutt
- 6 mnd nasal stenose og neseblødning

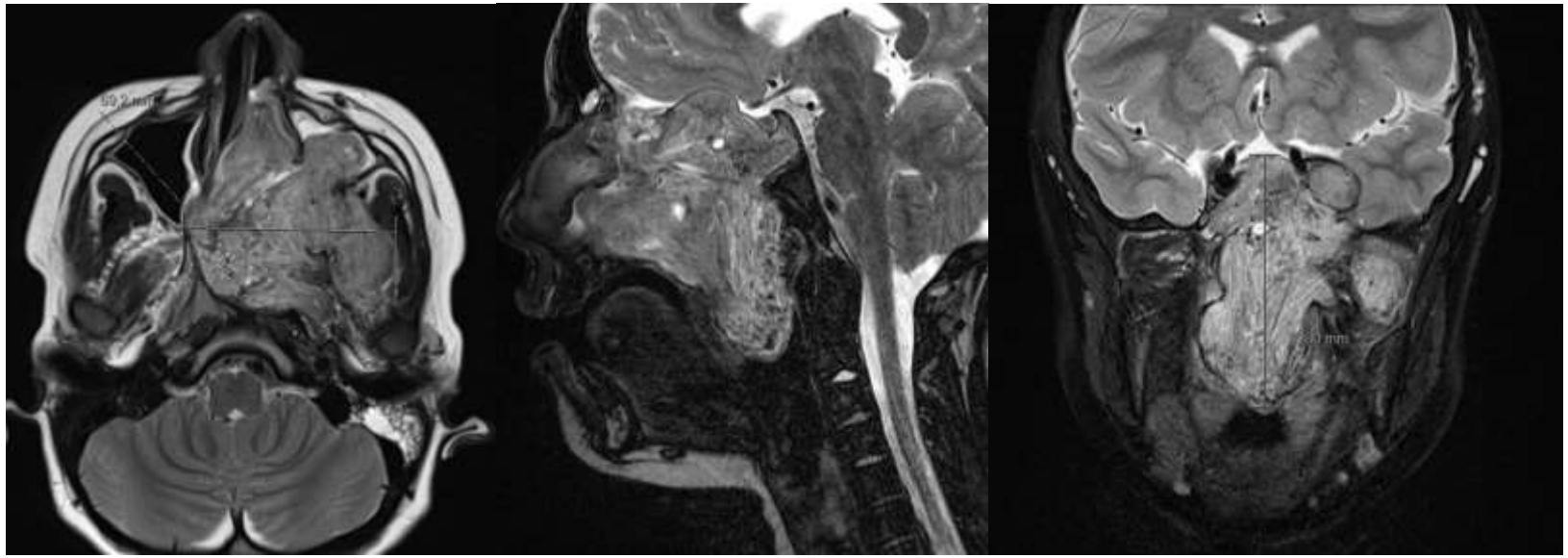

- Pre-operativ angiografi med coiling

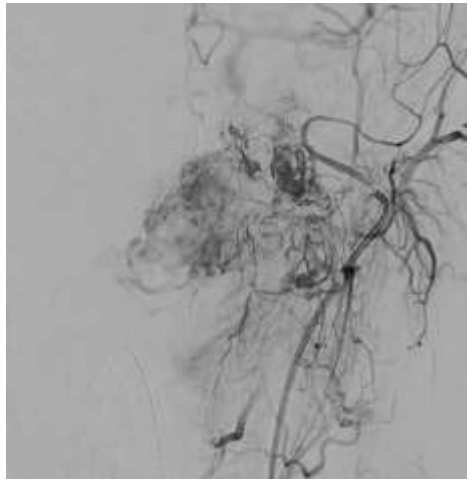

Oslo universitetssykehus

Fjerning av JAN med sublabial tilgang

- 11 år gutt
- 6 mnd nasal stenose og neseblødning

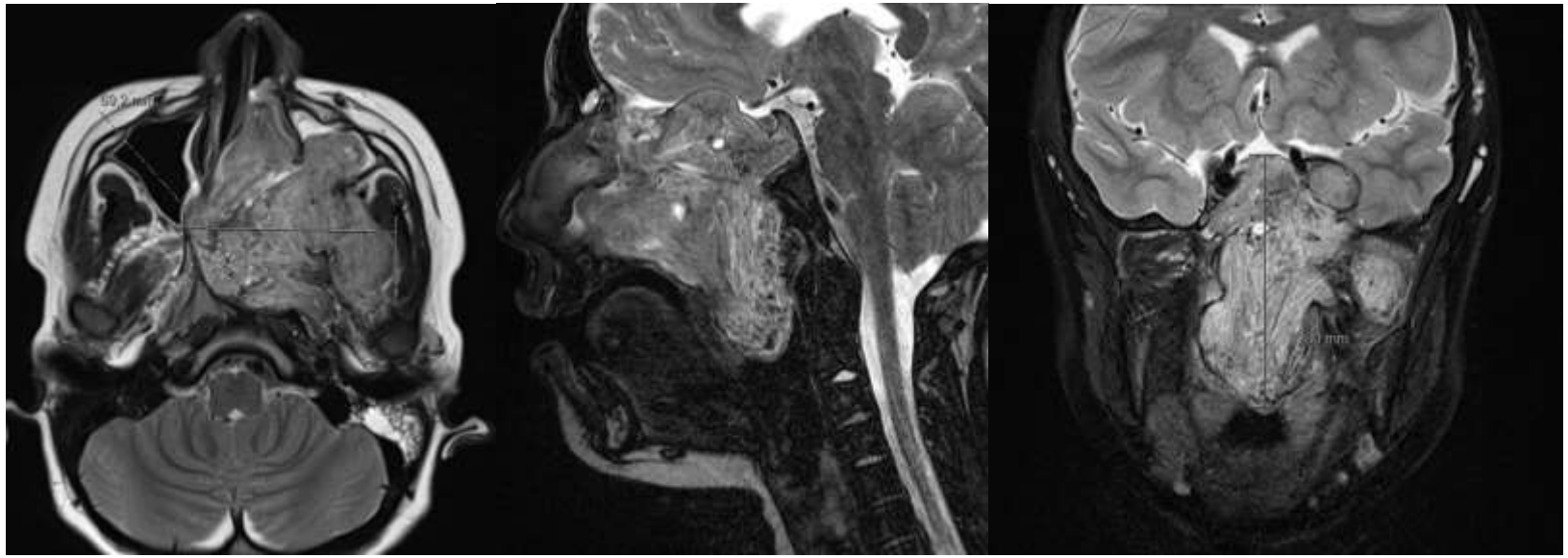

- MR dagen etter operasjon viste lien rest
- Endoskopisk fjernet

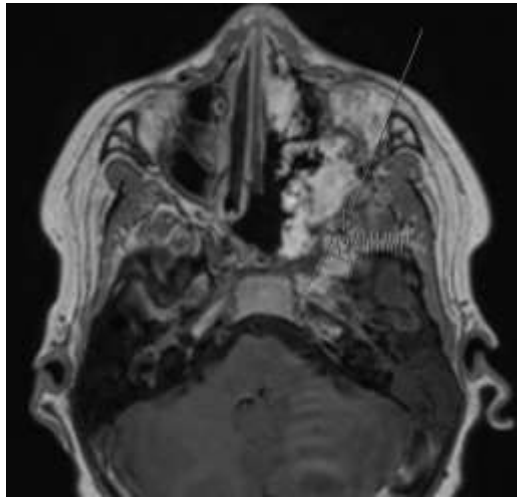

Oslo universitetssykehus

Orbita kirurgi

- Orbita dekompresjon
- N.opticus dekompresjon
- Orbita tumor

Orbita dekompresjon

- Orbita abscess

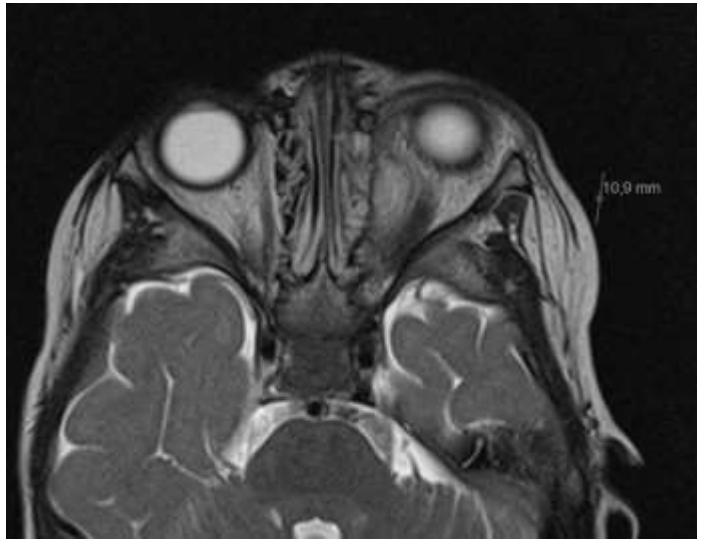

Oslo universitetssykehus

Orbita dekompresjon

- Graves disease

- Bilateral endoskopisk debulking

Oslo universitetssykehus

n. Opticus dekompresjon

- Blind i ve øye etter fallskade

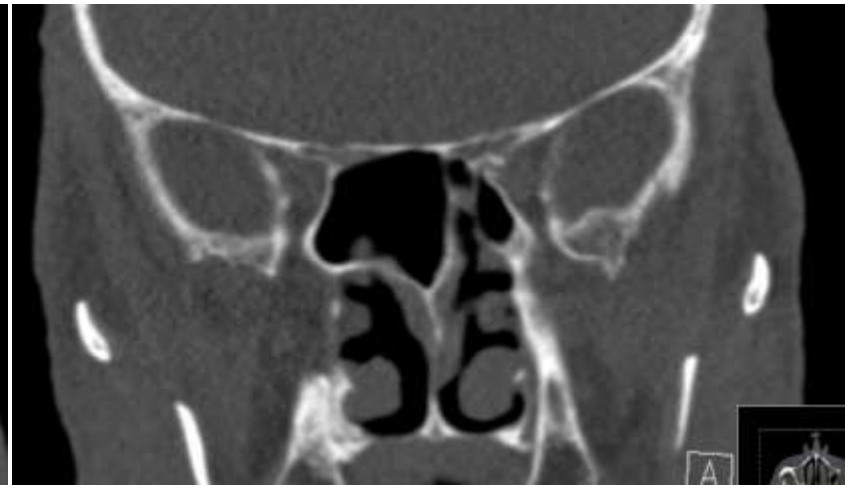

- Endoskopisk dekompresjon

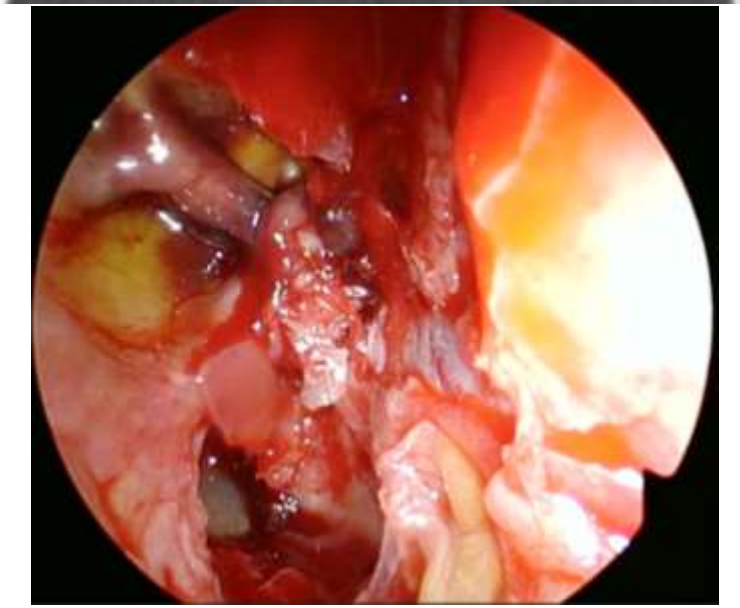

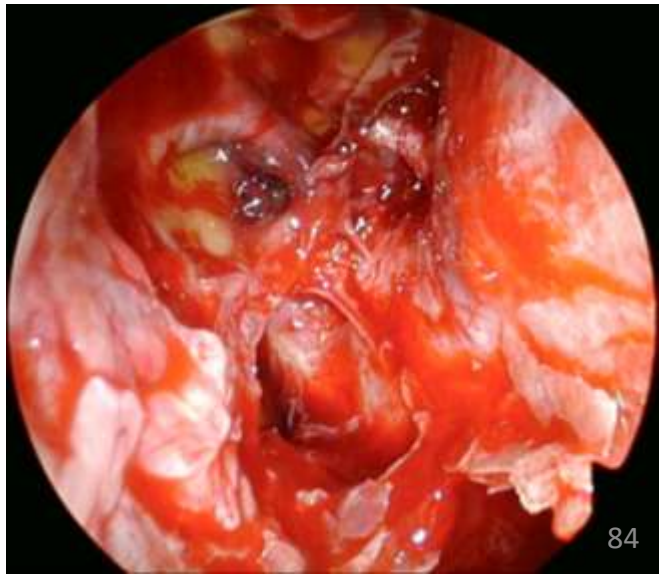

Oslo universitetssykehus

Orbita tumor

- Residiv/rest av juvenilt angiofibrom i hø orbita

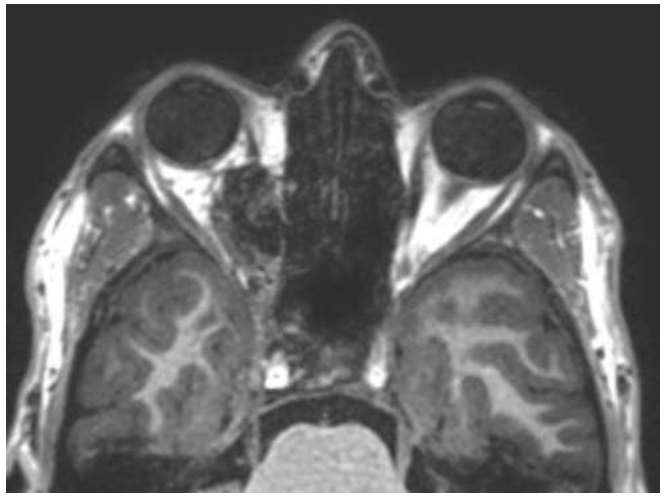

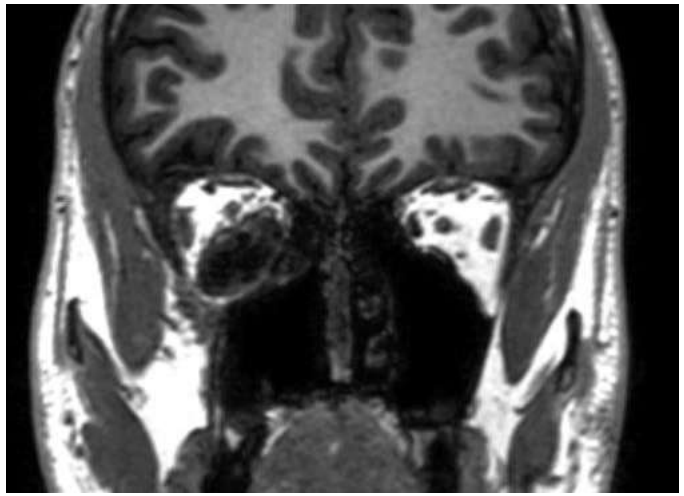

- Endoskopisk fjerning

(Peroperativ MR)

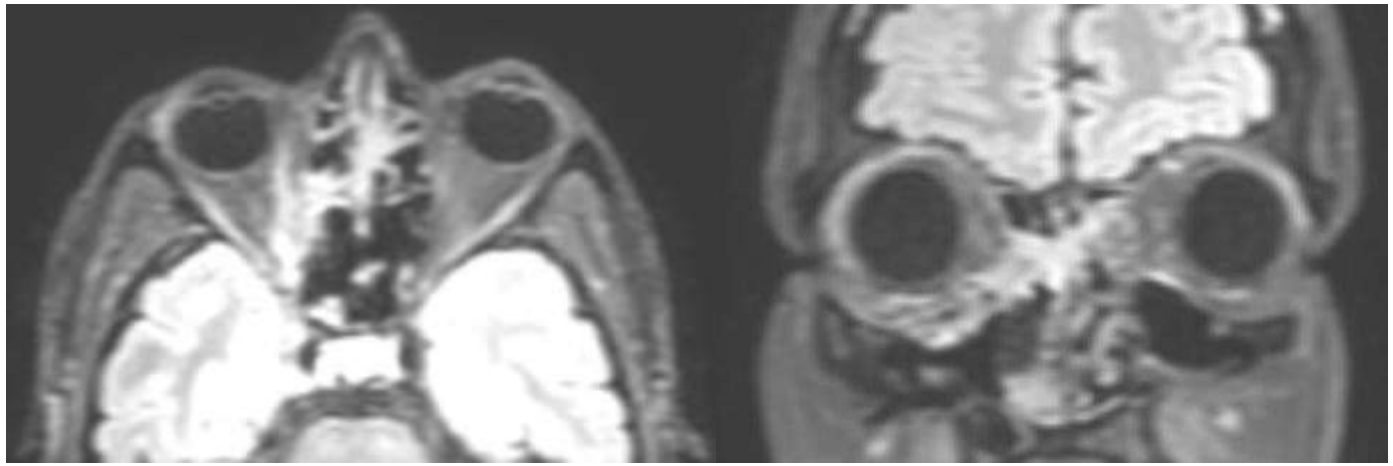

Orbita tumor

- Residiv/rest av juvenilt angiofibrom i hø orbita

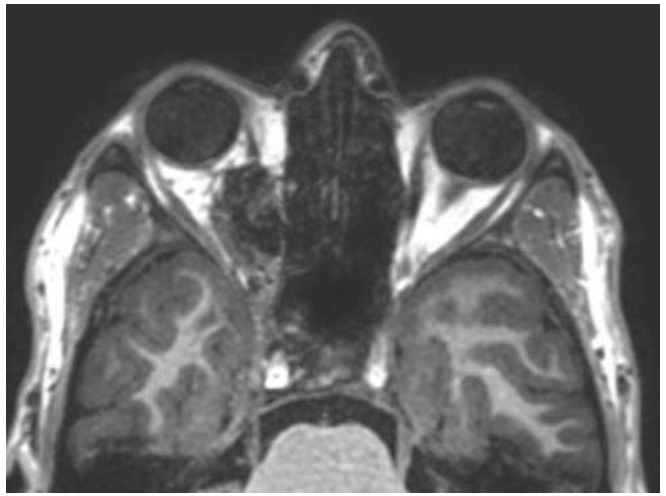

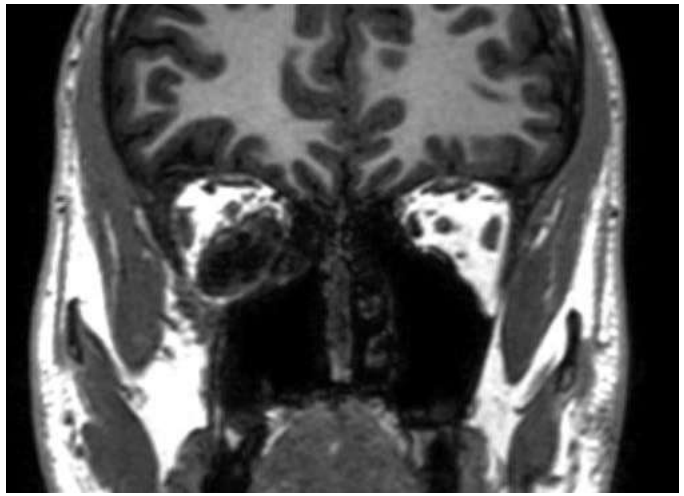

- Endoskopisk fjerning

(MR 5 år senere)

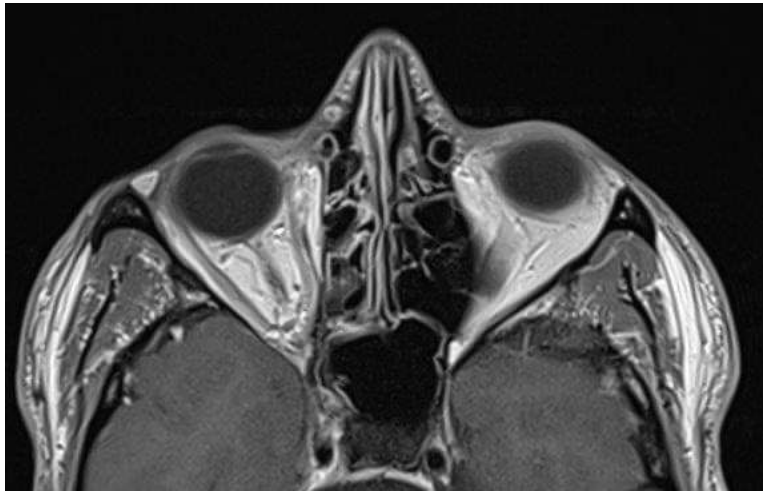

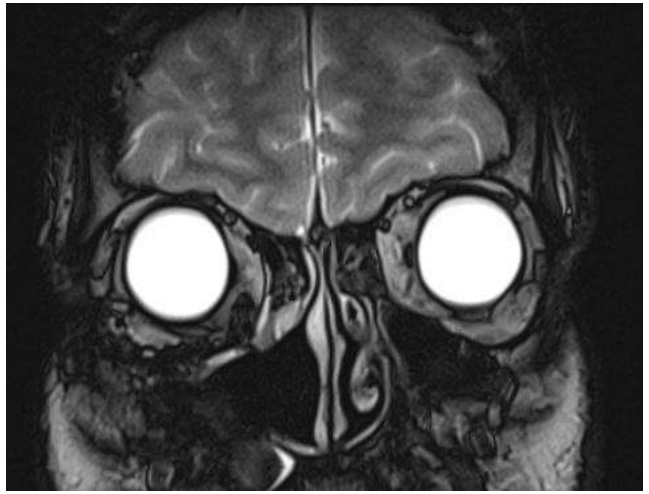

Orbita tumor

- Papillær thyroedea carsinom metastase til orbita

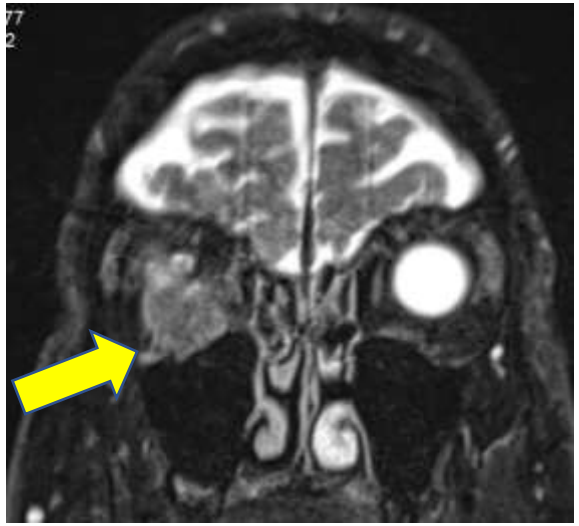

- Endoskopisk medial maxillæktomi og orbitoromi

TAKK